

Chapter 24. Treating Micromotion Hypomobility of the Atlantoaxial Joint in Patients with Whiplash Injury

Author: Jerry Hesch, MHS, PT, DPT, HSP

From the book: *Movement Integration - the Systemic Approach to Human Movement*

Authors: Martin Lundgren, Linus Johansson

Contributors: Gary Carter, Ása Áhman, Julian Baker, Cecilia Gustafsson, Lucas Henriksson, Lena Björnsdotter, Gary Ward, Jerry Hesch

About the Authors

Linus Johansson is a physiotherapist who specializes in holistic approaches to the human form through physical therapy and movement integration. He works with clients regularly to improve performance and address pain related problems and is also one of the creators behind the SOMA MOVE concept.

Martin Lundgren is a Board-Certified Structural Integrator and Movement Practitioner. With roots in Structural Integration and Anatomy in Motion, he has been developing new treatment systems and methods in recent years. Through his work with treatments and movement, he develops people's kinesthetic ability, performance, and well-being.

A paradigm-shifting, integrative approach to understanding body movement.

The ability to move with efficiency and agility has been an essential component to our evolution and survival as a species. It has enabled us to find food, fight threats, flee danger, and flourish both individually and collectively. Our body's intricate network of bones, muscles, tissues, and organs moves with great complexity. While traditional anatomy has relied on a reductionist frame for understanding these mechanisms in isolation, the contributors to *Movement Integration* take a more systemic, integrative approach. *Ensomatosis* is a new paradigm for comprehending movement from the perspective of the body's entirety. The body's many systems are understood as synchronized both internally and externally. Drawing on expertise in physiotherapy, somatics, sports science, Rolfing, myofascial therapy, craniosacral therapy, Pilates, and yoga, the authors assert that a more comprehensive understanding of movement is key to restoring the body's natural ability to move fluidly and painlessly. With over 150 images, the Color Illustration Model of Relative Movement provides a visual tool for understanding how joints interact with surrounding

structures (rather than in isolation). This is an ideal book for physiotherapists, massage therapists, structural integrators, coaches, as well as yoga and Pilates instructors. \$29.95 from Amazon.com

- Paperback: 272 pages
- Publisher: North Atlantic Books (February 18, 2020)
- Language: English
Publication date: 02/18/2020
- ISBN-10: 1623174651
- ISBN-13: 978-1623174651
- Product Dimensions: 8.4 x 0.4 x 10.8 inches
- Shipping Weight: 1.5 pounds

Table of Contents

Foreword 7

Acknowledgments 9

Part I

Chapter 1 The law of perspectives Linus Johansson 13

Chapter 2 The purpose of life and pain Linus Johansson 15

Chapter 3 One foot in front of the other Linus Johansson 20

Chapter 4 The principles of a new paradigm - Martin Lundgren 24

Chapter 5 Relationships Linus Johansson 32

Chapter 6 Oppositions Linus Johansson 49

Chapter 7 The Color Illustration Model: a new way to illustrate movement Martin Lundgren 53

Chapter 8 Gait made simple Martin Lundgren 57

Chapter 9 Ensomatosy Linus Johansson 84

Chapter 10 Ensomatosy visualized Linus Johansson 94

Chapter 11 To study ensomatosy Linus Johansson 101

Chapter 12 The positive intention Linus Johansson 105

Part II

Chapter 13 A more detailed look at posterior tilt of the ribcage Martin Lundgren 113

Chapter 14 My method Linus Johansson 118

Chapter 15 Soma Move® Linus Johansson 124

Chapter 16 A note on craniofacial development Martin Lundgren 132

Part III

Chapter 17 Variations in myofascial slings and continuities Gary Carter 139

Chapter 18	What is movement?	Åsa Åhman	155
Chapter 19	Fasciaism is on the rise!	Julian Baker	165
Chapter 20	What is movement?	Cecilia Gustafsson	174
Chapter 21	What is movement?	Lucas Henriksson	184
Chapter 22	What is movement?	Lena Björnsdotter	192
Chapter 23	What is the potential influence of the skeleton's movement on the fascial system?	Gary Ward	199
Chapter 24	Treating micromotion hypomobility of the atlantoaxial joint in patients with whiplash injury	Jerry Hesch	212
Index			223

Jerry Hesch, PT, HSP, MHS, DPT
HESCH INSTITUTE
25837 East Maple PL.
Aurora, Colorado 80018
Website: www.HeschInstitute.com
Email: jerryhesch@heschinstitute.com
Phone 303-366-9445 Mountain Time Zone

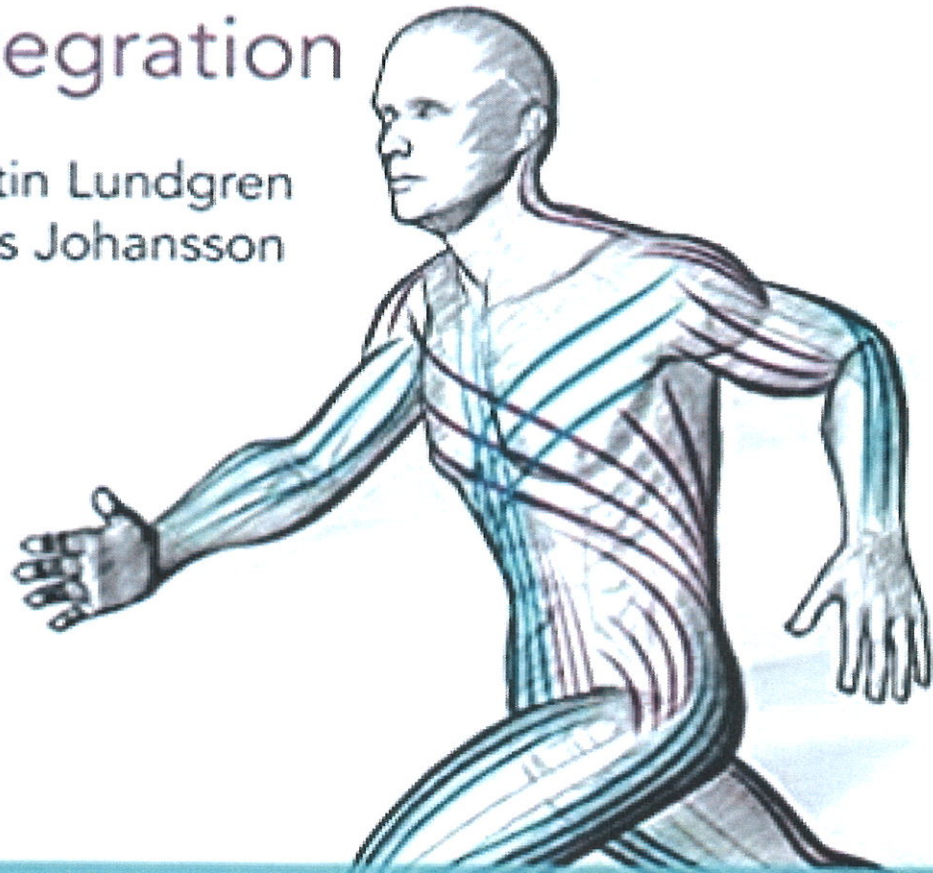
I treated myself very successfully for an upper cervical whiplash injury and do not find any source for this material in the literature so decided to publish a book chapter. This was published in November 2019 in Europe and available in the US February 2020. It includes self-treatment. Here is the disclaimer.

This is presented by Dr. Jerry Hesch, MHS, DPT, PT, HSP of Hesch institute in Aurora, Colorado. Jerry treats chronic pain using a whole-body Manual Therapy and educational approach. For information on scheduling an appointment with Dr. Hesch, MHS, PT, DPT please go to Website: www.HeschInstitute.com Dr. Hesch treats most conditions in three visits with a goal of making the chronic patients independent of healthcare. Please follow us on You Tube and Facebook at "Hesch Institute". Hesch Institute also provides Home Study Courses and hands-on workshops.

DISCLAIMER: The Written content or video has been made available for informational and educational purposes only. Jerry Hesch and Hesch Institute do not make any representation or warranties with respect to the accuracy, applicability, fitness, or completeness of the written content or video. Jerry Hesch and Hesch Institute does not warrant the performance, effectiveness or applicability of any written content or video. The written content or video is not intended to be a substitute for professional medical advice, diagnosis, or treatment. Always seek the advice of your physician or other qualified health provider with any questions you may have regarding a medical condition. Never disregard professional medical advice or delay in seeking it because of something you have read or seen on the Site. Jerry Hesch and Hesch Institute hereby disclaims any and all liability to any party for any direct, indirect, implied, punitive, special, incidental or other consequential damages arising directly or indirectly from any use of the written content or video, which is provided as is, and without warranties.

movement integration

Martin Lundgren
Linus Johansson



the systemic approach to
human movement

Contributors:

Gary Carter, Åsa Ahman, Julian Baker, Cecilia Gustafsson, Lucas Henriksson,
Lena Björnsdóttir, Gary Ward, Jerry Hesch

A paradigm-shifting, integrative approach to understanding body movement

The ability to move with efficiency and agility has been an essential component to our evolution and survival as a species. It has enabled us to find food, fight threats, flee danger, and flourish both individually and collectively. Our body's intricate network of bones, muscles, tissues, and organs moves with great complexity. While traditional anatomy has relied on a reductionist frame for understanding these mechanisms in isolation, the contributors to *Movement Integration* take a more systemic, integrative approach.


Ensomatosis is a new paradigm for comprehending movement from the perspective of the body's entirety. The body's many systems are understood as synchronized both internally and externally. Drawing on expertise in physiotherapy, somatics, sports science, Rolfing, myofascial therapy, craniosacral therapy, Pilates, and yoga, the authors assert that a more comprehensive understanding of movement is key to restoring the body's natural ability to move fluidly and painlessly.

With over 150 images, the **Color Illustration Model** provides a visual tool for understanding how joints interact with surrounding structures (rather than in isolation). This is an ideal book for physiotherapists, massage therapists, structural integrators, coaches, as well as yoga and Pilates instructors.

For more information, visit movementintegrationbook.com.




Linus Johansson is a physiotherapist, movement practitioner, and movement integrator. He works with patients in his clinic, presents workshops, and educates other therapists and trainers. Johansson is the author of several books and together with Cecilia Gustafsson has developed the movement concept SOMA MOVE®.



Martin Lundgren is a Board Certified Structural Integrator (ATSI/KMI) and Movement Practitioner. With roots in Structural Integration and Anatomy in Motion, he has been developing new treatment systems and treatment methods in recent years. As well as educating other therapists and trainers, he develops people's kinesthetic ability, performance, and well-being in his clinic through his way of working with treatments and movement.

 **lotus**
publishing
Chichester, England

 North Atlantic Books
Berkeley, California

Health / Human Anatomy & Physiology

www.northatlanticbooks.com

US \$32.95 / \$43.95 CAN

ISBN 978-1-62317-465-1

5 3 2 9 5



9 781623 174651



Jerry Hesch



Jerry Hesch is a Colorado licensed physical therapist with a bachelor's of science in physical therapy from University of New Mexico, and a master's of health science from the University of Indianapolis. He completed a doctorate in physical therapy

from AT Still University.

Dr. Hesch has developed the Hesch Method over more than 35 years of clinical practice. The Hesch Method is a distinct and gentler approach than the joint adjustment model and has described numerous patterns of motion dysfunction that exist in patterns throughout the body. The Hesch Method treats from a whole-body approach rather than focusing only

on where it hurts. In the lumbopelvic area alone, Dr. Hesch has identified more than a dozen faulty motion patterns not yet described in the literature and developed treatment methods. He has reinterpreted the mechanics of traumatic birth named pubic symphysis diastasis (or pubic joint or symphyseal diastasis) and has developed unique treatment. He has also developed a unique approach to treating the atlantoaxial joint.

Dr. Hesch has taught more than 100 seminars since 1985, instructing clinicians in application of the Hesch Method to assess and treat the pelvis, sacroiliac joint, and lumbar spine. He has also developed learning materials on his advanced body of work, which allows the clinician to apply manual therapy using a whole-body approach. He is currently involved in teaching and writing, and is also accepting patients with complex chronic pain.

CHAPTER 24

Treating micromotion hypomobility of the atlantoaxial joint in patients with whiplash injury

Jerry Hesch

Introduction

A pattern of compression and hyperextension at the upper cervical spine, especially at the atlantoaxial (C1–C2) joint, is frequently encountered via manual evaluation by this author in an outpatient physical

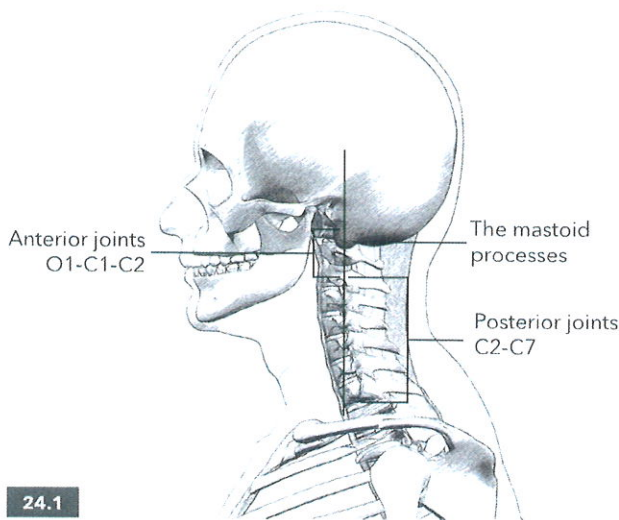
therapy practice. This pattern is under-represented in the literature and public domain based on searches on www.PubMed.gov, www.Google.com and www.YouTube.com utilizing key words “atlas, atlantoaxial, extension, hyperextension, flexion, compression, traction, distraction” (date of search December 31, 2018).

However, many resources are readily encountered when the term “rotation atlas” is utilized. This includes evaluation and treatment of rotational asymmetry of the atlas. Rotation is a relevant movement of the atlas and is well represented in web searches whereas distraction and extension hypomobility of the atlas is apparently under-diagnosed and therefore undertreated. This author encounters traction restriction with the upper cervical spine in mild extension frequently in the population with whiplash and cervicogenic headache. This chapter focuses on evaluation and treatment of the upper cervical spine for extension distraction hypomobility.

Articular shape of the occipitoatlantal and atlantoaxial joint

A brief review of the articular anatomy of the occipitoatlantal joint (OAJ) and atlantoaxial joint (AAJ) will be presented (figures 24.1–5). For a detailed review see Bogduk and Mercer,¹ Dalton,² and Neumann.³ Bogduk and Mercer serve as the primary source for the following review.

The OAJ and AAJ lie directly beneath the mastoid processes in the anterior aspect of the spinal

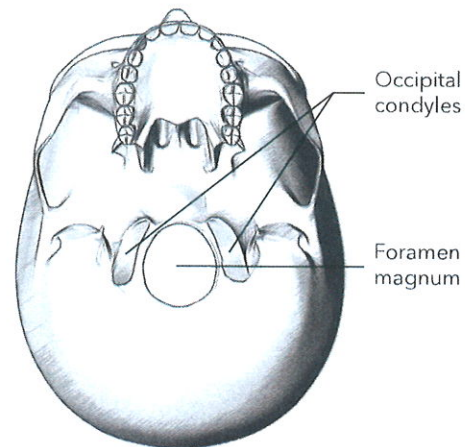


24.1

The occipitoatlantal joint is medial to the mastoid processes whereas the atlantoaxial joint is directly beneath the mastoid process. In contrast, the facet joints of the mid and lower cervical spine lie posterior to the mastoid processes.

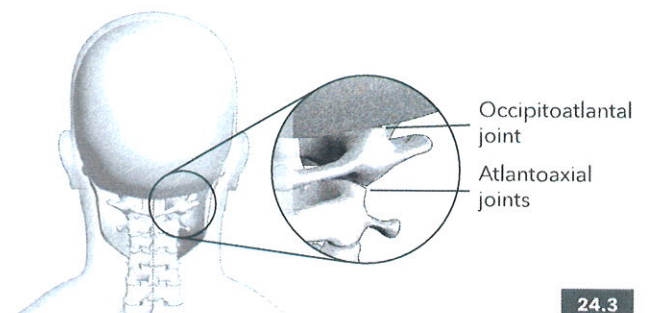
column whereas the C2–C7 facet joints lie in the posterior portion (figure 24.1). This distinction is important when applying traction to isolate the upper cervical spine.

The first cervical vertebra, named the atlas (figures 24.4, 24.5), is a ring-like structure designed to transmit forces from the head to the neck. It has two lateral concave facets that are shaped somewhat like a peanut having two connected lobes. These articulate with the convex tubercles of the occiput (figures 24.2, 24.3). The atlas moves in concert with the occiput. The posterior aspect of the anterior arch of the atlas has cartilage and articulates with the anterior aspect of the dens (aka odontoid) process of C2 (figures 24.4, 24.5). There are two lateral facets in which the inferior aspect of the lateral mass of the atlas articulates with the axis. These facet joints are plane-like (figures 24.3, 24.4); however, the cartilage is convex on each surface.




24.2

Convex occipital condyles that articulate with concave facets of the atlas.

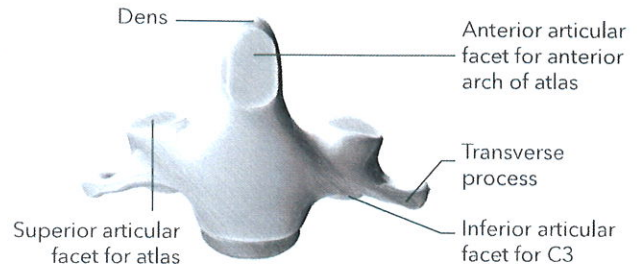


24.3


Occipitoatlantal and atlantoaxial joints.



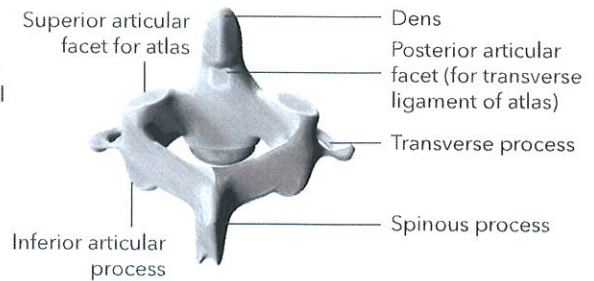
Atlas (C1): superior view



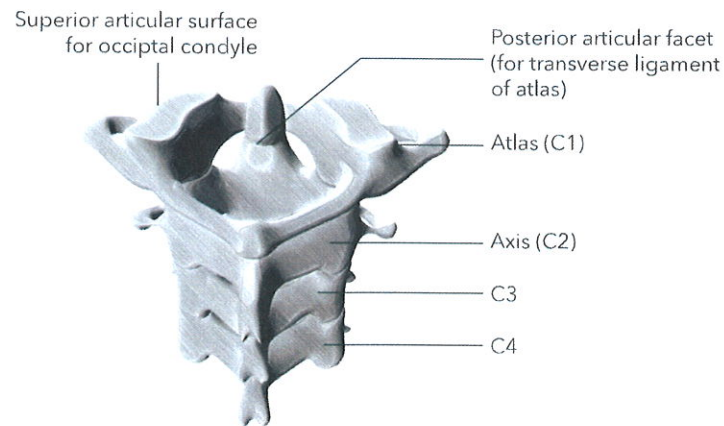
Axis (C2): anterior view



Atlas (C1): inferior view



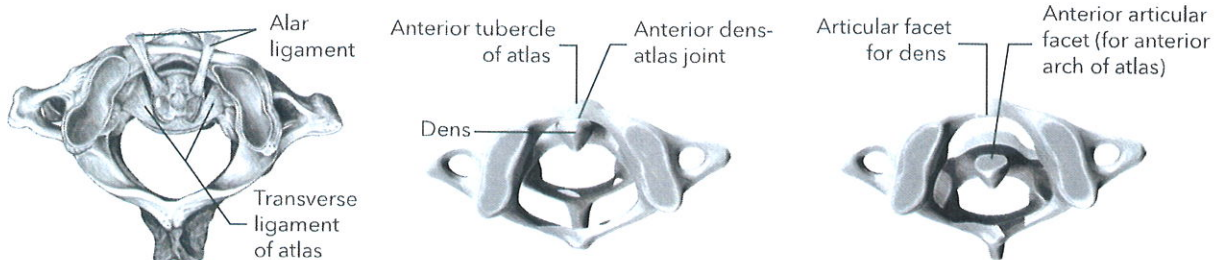
Axis (C2): posterosuperior view



Upper cervical vertebrae, assembled: posterosuperior view

24.4

Articular anatomy of the atlas and axis.



24.5

Ligaments of the atlantoaxial joints.

Macromotion and micromotion

Active flexion in the upper cervical spine is under conscious control and is a macromotion/gross motion. It can also be described as osteokinematic or “observable movement or observable effect of bone movement.” When the upper cervical spine moves in forward bending/flexion a rather small amount of flexion motion first occurs in the OAJ and then flexion motion occurs in the C1–C2 articulation and then continues downward. Micromotions are very small movements, which may accompany gross physiological motion but can also be elicited passively by an external force and cannot be isolated with conscious intent. There is a micromotion of distraction that occurs in the posterior aspects of these articulations while there is a micromotion of compression that occurs in the anterior aspects of these joints with cervical flexion. The other micromotion that accompanies these motions is posterior glide and roll occurring with flexion. Rolling and spin are also described as arthrokinematic motion. Roll and spin will not be addressed because these are movements that cannot be isolated with external forces. Arthrokinematic motions are a necessary part of macromotion physiologic movement. Arthrokinematic motions occur within the joint surfaces and has the following aspects according to Mulligan:⁴

- ✦ Unobservable articular accessory motion between adjacent joint surfaces such as roll, segmental glide, and spin.
- ✦ These accessory motions take place with all active and passive movements and are necessary for full, pain free range of motion.
- ✦ Arthrokinematic motion cannot occur independently or voluntarily and if restricted, can limit active physiological movement.
- ✦ Arthrokinematic motion occurs anywhere along the range of motion.

Like arthrokinematic motions, joint play is a micromotion that is not observed and is not under conscious control, thus cannot be isolated with muscle contraction. Joint play can only be evaluated passively. The various types of joint play include distraction, glide in extremities and unisegmental glide in the spine, and

overpressure such as at the extremes of joint flexion, extension, and rotation, etc. Joint play is utilized to evaluate micromotion mobility, or hypomobility. Joint play can only be evaluated when the available slack has been taken out of the joint via glide, traction, or overpressure. This chapter will focus on traction of the upper cervical spine performed with the neck in neutral and in 10° of flexion and 10° of extension to optimize isolation of the AAJ. The term traction end feel relates to two mobility states with no gray areas in-between; mobile or hypomobile. It is the nature of this joint to present with either extreme and this property makes for lucid evaluation.

Upper cervical traction end-feel is a unique type of joint play and is a normal physiologic motion when tested at 10° of flexion and extension. This motion is not subtle. The motion is readily observable as is the distinct lack of motion when present. With specific manual contact on the temporoparietal region, distraction is isolated to the upper cervical joints. Following injury this joint play can become hypomobile/blocked and requires passive evaluation and passive treatment, which will be addressed later in the chapter. The term hypomobile in this context is the same as blocked mobility. Restricted mobility at the OAJ is rare whereas restriction at the AAJ is frequently encountered, such as in patients who have had a whiplash injury. Clearing the OA joint and isolating the AAJ is described later in the text. Additional information on principles of joint structure and function can be found.^{2,3,4,5}

In order to isolate traction to the AAJ, contact must be made on the temporoparietal region (figures 24.6, 24.7). When AAJ traction hypomobility is encountered in neutral (figure 24.7) and in 10° of extension (figure 24.9), the atlas is presumed to be stuck at the end range of physiologic extension. This author intentionally avoids the subluxation explanatory model. Unfortunately, there is a paucity of published literature on the topic of compressed, hyperextended AAJ including evaluation and treatment per pubmed.gov literature search using the key words “atlas, atlantoaxial, flexion, extension, traction, distraction, traction, compression, hypomobility” (search date November 27, 2018). There is, however, biomechanical literature indicating that flexion at the AAJ is 8° and extension

is 10°,⁶ and 11.5° flexion and 10.9° extension, 38.9° of unilateral rotation and 6.7° of lateral bending according to Panjabi et al.⁷ To review: the atlas forms three articulations with the axis. When there is motion at the lateral atlantoaxial facet joints there is also movement at the anterior articulation of the dens and atlas. With rotation of the atlas there is up to 3 mm of vertical glide at the anterior joint.⁸ Bogduk and Mercer¹ (p. 176) also report upward motion of the atlas on the dens based on joint shape, “The odontoid process is curved slightly posteriorly. This shape allows the anterior arch of the atlas to slide upward and slightly backward, thereby allowing the atlas to extend.” According to Neumann³ (p. 281), flexion at the AAJ consists of superior distraction of the spinous process of the atlas and downward pivoting at the lateral facets and at the anterior dens-atlas articulation. Extension induces the opposite. Motion in the upper cervical spine has been objectively measured.

However, paradoxical motion of the atlas has been elaborated upon by Bogduk and Mercer¹ (p. 177): flexion of the head can induce flexion or extension of the atlas. This is based on anatomical variation and difference in the location of weight bearing of occiput on atlas. The biconvex shape of the lateral facets suggests that weight bearing anterior or posterior to the apex would predict opposite motion coupling. This may partially explain why traction isolating the axis can be limited in slight flexion or in slight extension after injury such as whiplash. Nonetheless, the most common presentation is one in which traction is hypomobile when tested in neutral and in extension.

Contraindications to evaluation and treatment of the atlantoaxial joint

The same contraindications to upper cervical manipulation apply to passive joint testing and treatment of the upper cervical spine and has been described and is abbreviated below.⁹ The reader is encouraged to review the detailed elaboration from the World Health Organization Guidelines.

Inflammatory conditions, such as rheumatoid arthritis, seronegative spondyloarthropathies, demineralization or ligamentous laxity with anatomical subluxation or dislocation, represent an absolute contraindication to joint manipulation in anatomical regions of involvement. Other contraindications include:

1. anomalies such as dens hypoplasia, unstable os odontoideum, etc. This includes developmental anomalies such as Down syndrome, etc.
2. acute fracture
3. spinal cord tumor
4. acute infection such as osteomyelitis, septic discitis, and tuberculosis of the spine
5. meningeal tumor
6. hematomas, whether spinal cord or intracanalicular
7. malignancy of the spine
8. frank disc herniation with accompanying signs of progressive neurological deficit
9. basilar invagination of the upper cervical spine
10. Arnold–Chiari malformation of the upper cervical spine
11. dislocation of a vertebra
12. aggressive types of benign tumors, such as an aneurysmal bone cyst, giant cell tumor, osteblastoma or osteoid osteoma
13. internal fixation/stabilization devices
14. neoplastic disease of muscle or other soft tissue
15. positive Kernig’s or Lhermitte’s signs
16. congenital, generalized hypermobility
17. signs or patterns of instability
18. syringomyelia
19. hydrocephalus of unknown etiology
20. diastematomyelia
21. cauda equina syndrome

Mobility testing of the upper cervical spine

Prior to treating the AAJ, the OAJ is evaluated and treated if restriction is encountered. Treatment of the OAJ is beyond the scope of this chapter though there are numerous texts and online resources. The following tests are performed bilaterally in supine in order to relatively unweight the joints and reduce the effects of gravity.


Less force is required when mobility testing is performed in supine as opposed in sitting. The induced motions are very small, and the clinician should attempt to minimize any motion occurring into the mid or lower cervical spine. These tests should be performed very gently.

- ✦ With thumb pad on the anterior surface of the mastoid, an anterior to posterior spring test is performed to evaluate rotation.
- ✦ The pad of the index finger is placed beneath the mastoid process and a superior spring test is imparted to evaluate side bending joint play.
- ✦ Open hand digital or palmar grip of the occiput bilaterally is used with a posterior to anterior lift.
- ✦ Open hand digital or palmar grip of the occiput bilaterally is used with left and right side-glide.

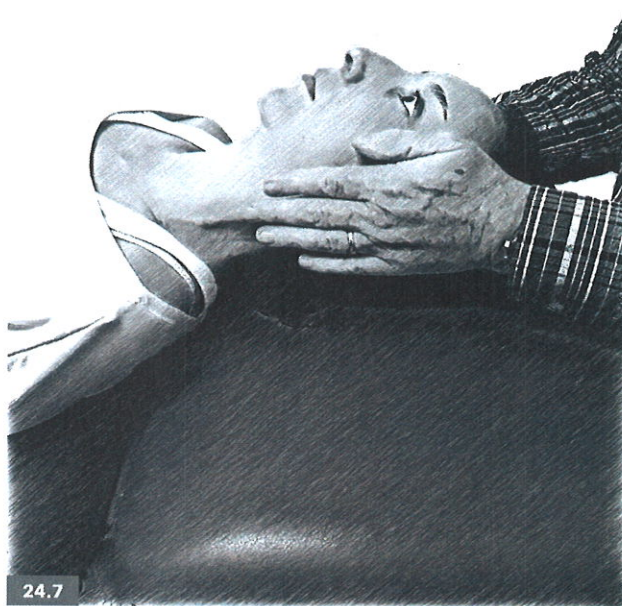The following tests are used to isolate the AAJ and are performed bilaterally in supine. They can be repeated at C3.

- ✦ The lateral tip of the transverse process is located just below the mastoid processes. Left and right side-glide mobility is evaluated with the pad of the index finger.
- ✦ The undersurface of the transverse processes is palpated bilaterally with the pad of the index finger. Lift up one side and then the other to induce rotation.
- ✦ Palpate the prominent midline spinous process of C2. It is easily located beneath the occiput whereas C1 spinous process is not as prominent and is deeper. The head must be flexed slightly to expose it. Contact with the pad of the index finger and apply an anterior glide force.
- ✦ Use digital or palmar contact bilaterally at the temporoparietal (figure 24.6) region just above and anterior to the mastoid, avoiding contact with the occiput. Test with the neck in neutral, 10° of passive flexion and 10° of passive extension (figures 24.7–24.9). Apply traction to take up the slack. If you are unable to take up the slack the joint is hypomobile and requires treatment. If you can take up the slack to a natural stop, but there is no additional

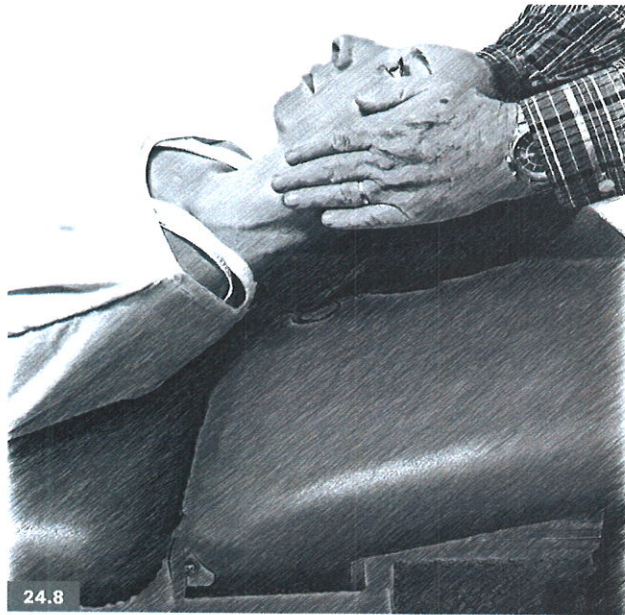movement with the spring test, the joint requires treatment. Note that this test may be positive in the presence of a restricted OAJ in which the special tests for the OAJ would also be positive.



Contact on the temporoparietal region above and anterior to the mastoid processes will isolate traction force to the upper cervical spine.



Manual traction with neck in neutral. The head is supported by the table. Note the contact on the temporoparietal region.



24.8 Manual traction with head in 10° of flexion. The head can be supported by an adjustable headpiece or with a low pillow. Note the contact on the temporoparietal region.



24.9 Manual traction with neck in 10° of extension. The head can be supported by an adjustable headpiece or with the head off the table resting on a pillow in the lap of the clinician. Note the contact on the temporoparietal region.

Hyperextension compression of the upper cervical spine

The presumed mechanism of injury involves a passive hyperextension force to the upper cervical spine, such as via a fall, motor vehicle accident, or repetitive trauma.

The most common presentation of upper cervical hypomobility is hyperextension of the AAJ in which traction performed in neutral (figure 24.7) and in 10° of extension (figure 24.9) is hypomobile, whereas traction performed in varying degrees of flexion is of normal mobility. Testing at 10° of flexion (figure 24.8) and extension allows relative isolation of the AAJ and the traction takes up the slack in the OA joint further isolating the AAJ. The temporoparietal manual contact isolates motion to the upper cervical joints. A traction force is applied gently and slowly until the slack is taken out and motion has ceased. This requires approximately 10–15 lb (4.5–6.8 kg) of tension depending on body morphology. In order to develop a felt sense of this force, one can practice by attaching a cervical traction halter onto a fixed fish scale. Alternatively, one could practice on a 10 lb/4.5 kg sack of flour. Note that the average force applied in order to perceive taking up the slack via traction will be slightly greater than the weight of the head due to friction. After that, practice on several asymptomatic individuals should yield an appreciation of normal mobility. Testing the patient population will yield an appreciation of hypomobility.

Taking up the slack occurs in both the AAJ and in the OAJ. In testing, once the slack is taken up (10–12 lb/4.5–5.4 kg) an additional traction force is induced using the same amount of force as was used to take up the slack (additional 10–12 lb/4.5–5.4 kg). The second part of the test evaluates force transmission through the AAJ. The hallmark of passive force translating through the upper cervical into the rest of the body in a non-restricted upper cervical spine is observable movement through the body as distal as in the feet. If the AAJ is hypomobile, movement will not be perceived and it will not be possible to take up the slack. This is not a subtle phenomenon, as a moderate increase in force will still fail to induce mobility. It seems reasonable that the passive testing isolates upper cervical motion because the force is very mild in contrast to studies that recommend 10% of body weight as ideal,¹⁰ and up to 50% of practitioner's body weight¹¹ for performing traction to the mid and lower cervical spine. Furthermore, the average human head only weighs 9.9–11 lb/4.5–5 kg,¹² based on cadaveric study in which the neck was sectioned at C3. That such a small force can induce movement throughout the whole body in a normal population may initially appear to be counterintuitive; however, with a little bit of

experience the reader should be able to appreciate the validity and utility thereof.

Treatment for a hypomobile atlantoaxial joint

Treatment is always performed close to the motion barrier but only in a direction that does allow traction mobility. If traction is hypomobile in neutral (figure 24.7) and in extension (figure 24.9) it is treated in flexion (figure 24.8). If traction is hypomobile in neutral and flexion it is treated in extension. Restricted traction in extension and in neutral is the most common presentation and is treated with manual traction applied at 10° flexion (figure 24.9), propped on a pillow or using an adjustable headpiece, with a specific temporoparietal hand-hold (figure 24.6) used to isolate force to the anterior portion of the upper cervical spine. The force is held for five minutes. The amount of force just matches the available movement of the head and neck and is appropriately described as “very gentle” and averages 10–12 lb/5.4 kg. It is important to mention that the upper two joints (OA and atlantoaxial) are anterior to the facet joints of the mid and lower cervical spine (C3–C7). The AAJ and OA joints are inferior to the mastoid process. Therefore, the hand contact must be very specific in order to avoid force application behind the mastoid. A palmar contact is applied to the temporoparietal region and the direction of pull is toward the vertex. This manual hold is in contrast with traditional manual cervical traction in which traction is applied via contact on the occiput. This important concept of contact above and anterior to the mastoid for upper cervical isolation has not been encountered in the literature and appears to be underappreciated in the clinical domain.

After treatment, traction mobility is retested in the prior restricted positions of neutral and 10° of extension. Only one visit for manual intervention is typical for restoring normal passive mobility. The client is also given isolated upper cervical exercises and self-traction to be performed while lying in a neck cradle named Doctor Riter’s Real-Ease® (real-ease.com, Torrance, CA). The neck cradle allows easy isolation of upper cervical movement. A two-inch diameter rolled towel under the mid cervical spine is an inexpensive alternative. These exercises and self-traction can be viewed on www.YouTube.com

by searching, “Hesch Upper Cervical Exercises”). The exercises and self-mobilization are also detailed in the case study below.

Treatment bullet points

- ✦ Inform the patient that they are to report any adverse or unusual response to testing and treatment, such as discomfort, light-headedness, dizziness, visual blurring, tingling or numbness, etc. Inform them that the procedure must be discontinued if these should occur.
- ✦ Determine if hypomobile traction test occurs in 10° of flexion or 10° of extension.
- ✦ If there is traction hypomobility in extension, passively position the head in 10° of flexion.
- ✦ If there is traction hypomobility in flexion, passively position the head in 10° of extension.
- ✦ Contact the head with bilateral palmar contact at the temporoparietal region. This is just above and anterior to the mastoid processes. Avoid occipital contact.
- ✦ Take up the slack by imparting 10–12 lb/5.4 kg to a natural stop.
- ✦ Maintain traction force for five minutes.
- ✦ Retest traction mobility in the position in which it was hypomobile.
- ✦ If mobility is restored proceed to instruct in self-management as described above and in the case study.
- ✦ Schedule follow up visit to reevaluate and review self-management.

Case study

A 66-year-old massage therapist was treated once for hypomobility of the atlas with lack of traction joint play mobility in neutral and in 10° of extension. This is an interesting case study because the client had received twice-weekly chiropractic and osteopathic adjustments for 30 years with an estimated out of pocket expenditure exceeding \$50,000.00. The chiropractic treatment was specifically directed at the atlas. She reported that benefit of treatment was very short-term.

The client presented with a lack of upper cervical distraction in neutral and in 10° of extension but had

free mobility in 10° of flexion. In flexion the traction force translated through the body and foot motion was observed, thus the traction force was not blocked. She was treated with traction applied with palmar contact on the temporoparietal region bilaterally at 10° of flexion sustained for five minutes (figure 24.8). The amount of traction force applied equaled the amount needed to take up the slack. She responded very positively with a feeling of lightness and better alignment in her head and neck and freer cervical mobility. Passive testing revealed resolution of the hypomobility.

She was instructed in a home exercise program utilizing Doctor Riter's Real-Ease neck cradle which isolates free and easy motion to the upper cervical spine. Very small movements were encouraged in order to isolate the upper cervical spine. These consisted of manual vertical distraction for two minutes once weekly, 30 reps of the following exercises twice weekly: posterior glide coupled with flexion, chin tucks, right and left rotation, right and left side-bending, right and left side-glide. She was also taught to combine sustained cervical spine retraction with repeated chin tucks (upper cervical flexion). Craniocervical retraction isolates upper cervical flexion while extending the mid and lower cervical spine according to Neumann³ (p. 282). The exercises with the neck cradle and self-traction are available on www.YouTube.com using the search terms, "Hesch Upper Cervical Exercises".

The client was seen twice and did not require passive treatment on the second visit. She provided the following feedback three weeks later:

I have had severe neck issues involving my upper cervical vertebrae since the age of 24 (42 years ago), when I had a bicycling accident. It was initially necessary for me to get chiropractic treatment every week, and sometimes twice a week, just to function.

My symptoms were severe occipital headaches, tightened jaw muscles, and vagus nerve involvement that caused heart racing, trouble regulating breathing and swallowing, and basically being stuck in sympathetic nervous system state! As the years went by, I saw many, many different chiropractors and osteopaths! When I first saw you, I was still seeing someone for adjustments at least every other week, if not every week. After you did your traction technique on my upper cervical spine, the relief

was amazing! My skull felt completely comfortable on top of my spine! I watched your video on self-treatment and have been doing it on myself each time I start to feel the headache or internal shakiness or racing heart. It works like magic! Thank you so much for this, I love being able to self-treat. It will save me a lot of time and money!

This is an atypical case study given the symptoms described as being vagally driven. The typical response to upper cervical traction is improved upper cervical traction joint play, greater ease of gross cervical motion, a sense of improved posture and reduction of cervicogenic headache.

Conclusion

Flexion and extension of the AAJ is a normal physiologic movement and can become restricted when coupled with compression in patients who have sustained cervical spine trauma. The manual contact is very specific in order to evaluate distraction of the AAJ. The literature and general body of knowledge has very limited information on this presentation. Treatment is very simple and direct and the same is true for self-management. A typical response to treatment is normalization of all directions of passive mobility of the atlas, with reduction of pain and a sense of optimized cervical posture along with greater ease in active cervical motion. This treatment model is based on very brief intervention and then instructing the patient in self-management. A case study illustrates these concepts. That the traction technique isolates the AAJ is presently only a theoretical construct. Additional research is needed to determine if this is valid and research on patient populations are needed to evaluate the validity, and utility of this technique.

References

1. Bogduk N, Mercer S; Biomechanics of the cervical spine. I: Normal kinematics. *Clinical Biomechanics* (Bristol, Avon) 2000, 15(9):633–648.
2. Dalton D; The vertebral column. In Levangie PK, Norkin CC, Lewek MD; *Joint Structure and Function: A Comprehensive Analysis, 6th edn*. Philadelphia: FA Davis Company, 2011, pp. 154–157.

3. Neumann D; Axial skeleton: osteology and arthrology. In: Neumann D; *Kinesiology of the Musculoskeletal System: Foundations for Rehabilitation, 3rd edn.* St Louis, MO: Mosby Elsevier, 2016, pp. 262–267, 277–286.
4. Mulligan E; Principles of Joint Mobilization. Power Point presentation. https://www.physio-pedia.com/images/c/c0/Principles_of_Joint_Mobilization.pdf (accessed November 26, 2018).
5. Threlkeld J; Basic structure and function of joints. In: Neumann D; *Kinesiology of the Musculoskeletal System: Foundations for Rehabilitation, 3rd edn.* St Louis, MO: Mosby Elsevier, 2016, pp. 25–40.
6. Abernethy J; Upper Cervical. Upper Cervical Spine Orthopedic Residency Lecture. Scottsdale Healthcare Osborn Campus, Scottsdale, AZ, January 9, 2014.
7. Panjabi M, Dvorak J, Duranceau J, Yamamoto I, Gerber M, Rauschnig W, et al; Three-dimensional movements of the upper cervical spine. *Spine* 1988, 3:726–730.
8. Boszczyk BM, Littlewood AP, Putz R; A geometrical model of vertical translation and alar ligament tension in atlanto-axial rotation. *European Spine Journal* 2012, 21(8):1575–1579. doi: 10.1007/s00586-012-2209-z.
9. WHO Guidelines to Spinal Manipulative Therapy. Specific Contraindications. http://wikichiro.org/en/index.php?title=WHO_Guidelines_-_Contraindications_to_SMT (accessed January 1, 2019).
10. Akinbo SR, Noronha CC, Okanlawon AO, Danesi MA; Effects of different cervical traction weights on neck pain and mobility. *Nigerian Postgraduate Medical Journal* 2006, 13(3):230–235.
11. Rammel ML; Relationship between therapist body weight and manual traction force on the cervical spine. *Journal of Orthopaedic and Sports Physical Therapy* 1989, 10(10):408–411.
12. Yee D; Mass of a human head. *The Physics Factbook*. <https://hypertextbook.com/facts/2006/DmitriyGekhman.shtml> (accessed November 29, 2018).

