

Dynamic Body[®]

*Exploring Form
Expanding Function*

Erik Dalton

CONTRIBUTING
AUTHORS

Judith Aston

Serge Gracovetsky

Robert E. Irvin

Gil Hedley

Jerry Hesch

Kai Hodeck

Craig Liebenson

Til Luchau

Aaron Mattes

Thomas Myers

Aline Newton

Divo G. Müller

Art Riggs

Robert Schleip

James Waslaski

Adjo Zorn

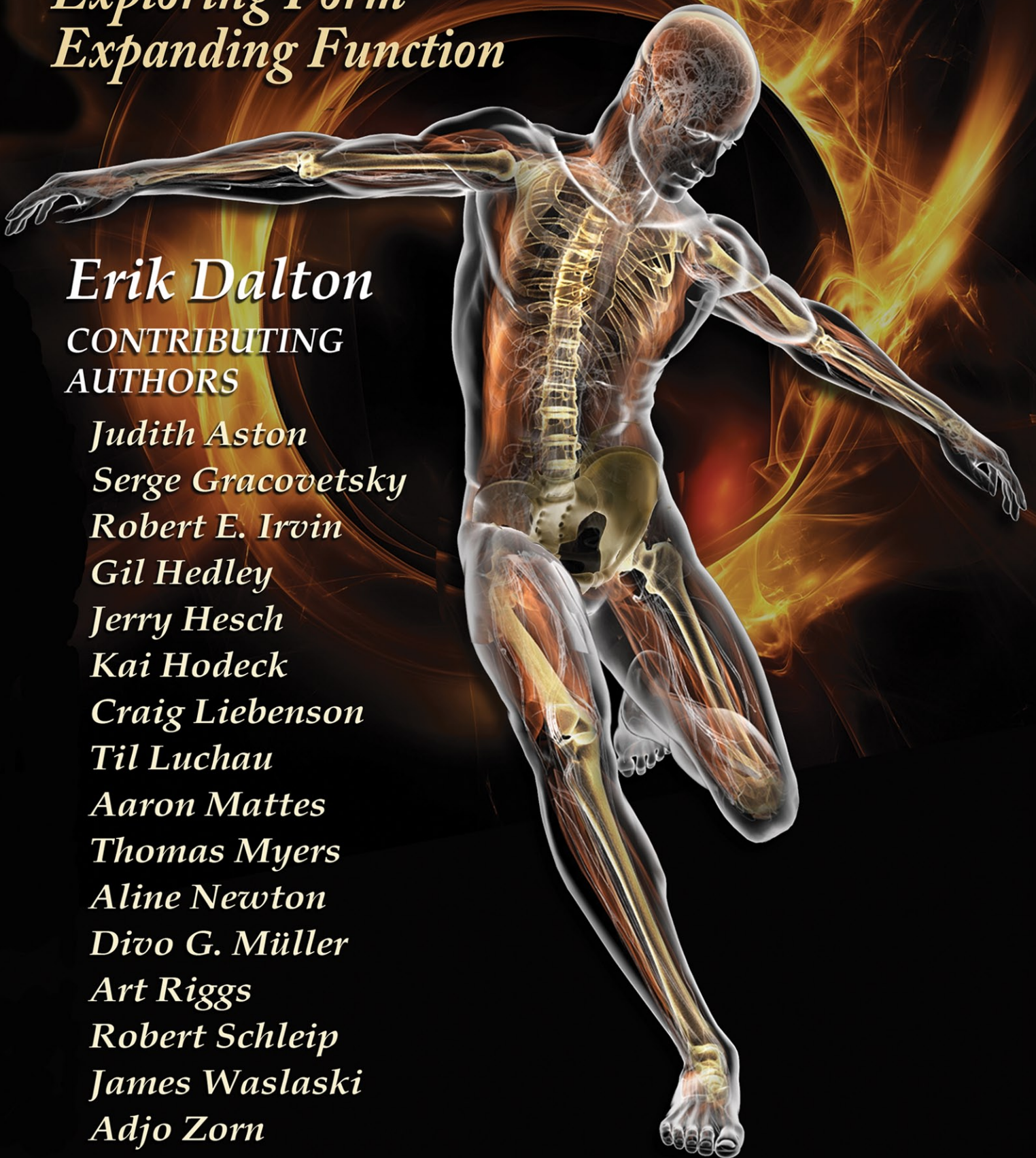

TABLE OF CONTENTS

Art Riggs 1	Jerry Hesch 190
Refine Your Touch	Sacral Torsion About an Oblique Axis
<i>Striking a Balance Between Relaxation and Intense Therapeutic Bodywork</i>	
Erik Dalton 12	Erik Dalton 232
May the Course be with You	Vicious Cycle
Judith Aston 28	Aline Newton 248
Aston Kinetics	Stabilization: The Core and Beyond
<i>A 360° by 360° Perspective of the Human Body</i>	
Til Luchau 54	James Waslaski 274
John Wayne, Marilyn Monroe, and Goldilocks	Treating Tendinosis Conditions
<i>Assessing Pelvis Movement in Walking</i>	<i>A Revolutionary 12 Step Approach</i>
Gil Hedley 62	Serge Gracovetsky 308
Reconsidering "The Fuzz"	The Coupled Motion of the Spine
<i>Notes on Distinguishing Normal and Abnormal Fascial Adhesions</i>	<i>Bipedalism versus Human Gait & Application to Sports Medicine</i>
Craig Liebenson 74	Erik Dalton 330
A Rehabilitation Roadmap	Human Silly Putty
Adjo Zorn / Kai Hodeck 96	Robert E. Irvin 342
Walk With Elastic Fascia	Enduring Relief of Chronic Pain
<i>Use the Springs In Your Step!</i>	<i>Using Orthotics to Correct Postural Imbalance</i>
Erik Dalton 124	Robert Schleip and Divo Gitta Müller 366
Well-Heeled	Fascial Fitness
	<i>Suggestions for a fascia-oriented training approach in sports and movement therapies</i>
Robert Schleip 136	Erik Dalton 378
Fascia As a Sensory Organ	Weak in the Knees
<i>A Target of Myofascial Manipulation</i>	
Thomas Myers 164	Aaron Mattes 394
An Introduction to Anatomy Trains	Active Isolated Stretching
<i>Myofascial Meridians</i>	<i>The Mattes Method</i>



Foreword


Concepts about the structure and function of the body and how it relates to the mind and emotions are strongly influenced by the environment in which we live and work. The rationalist view of the body and mind dates back to Aristotle (300 B.C.) and was later influenced by the widely adopted theories of people such as Galen (129-199 A.D.), René Descartes (1596-1650), and Isaac Newton (1642-1727). This view provides the underlying principles of orthodox medicine, which takes a mechanistic approach to healing, with the various body systems studied independently of one another, and the body viewed as a machine with parts to be fixed.

Unfortunately, tradition is hard to break and education changes slowly. Many contemporary anatomy and bodywork books still take this approach, and graduates may be indoctrinated into a rationalist viewpoint despite the collective research and understanding to the contrary.

Dynamic Body: Exploring Form, Expanding Function pulls apart this old model and provides the conceptual framework to understand what we already sense as bodyworkers, manual therapists, and massage professionals. We know that what walks into our practices is not a skin-wrapped collection of parts that can be fixed like a car at an auto shop, but a thinking, feeling, emotional, and physical spirit. In this book, you'll discover how these dynamic bodies work, not simply under the microscope or in the cadaver lab, but as complex, fully integrated, and very much *living* beings.

In our profession, we often hear adjectives such as “holistic,” “whole body,” “interconnected,” and “integrative” thrown about as an ideal in client treatment. Complementary and alternative therapies are slowly moving toward a view of the body, mind, and spirit as an integrated whole that, in turn, is integrated with its environment. We understand, on a visceral level, the complexity of our clients and the need to treat the total person. However, while this is a worthy ideal in theory, its practical application is much more difficult, especially as we lack any broad and commonly accepted models for incorporating these concepts into our clinical treatments.

How do we move away from the simple formulaic approaches to treatments that have characterized a longstanding rationalist view of the body? How do we develop a treatment approach that doesn't just address the health status of a small part of the body, but encompasses the structural, neurologic, and psycho-emotional aspects of a client's complaints? How can we even begin to consider our treatment options from this perspective, when the cause of a seemingly isolated complaint is so multifaceted?



Dynamic Body makes a bold leap into answering these questions by pulling together some of the top thought leaders in our profession. These forward-thinking researchers and clinicians have devoted their lives to answering questions that help us truly understand adjectives such as “holistic” and “integrated” for the first time. In these pages, they explore and help us understand the “dynamic body” from their diverse backgrounds and rich collective experience.

The contributors to this book are change agents – imaginative and innovative thinkers. They will push you to see the body in an entirely new light. Their insights will help you rethink what you thought was true of the body and challenge you to see your clients’ issues in a very different way. They weave together disparate ideas in unique ways in order to show us the fabric, if not the thread, of a new paradigm of the body. Along the way, you will find yourself redefining who you are as a bodyworker and massage professional.

As a director of both the World Massage Conference and Massage Therapy Radio, I’ve had the opportunity to interview hundreds of the top educators from around the world. So I can say with certainty that the contributors that Erik Dalton has brought together in creating *Dynamic Body* are truly the most novel thinkers in the profession.

You will immediately recognize many of these contributors as celebrities, the giants in our profession. Others may not have the same name recognition, but have been working out of the limelight, formulating their paradigms behind the scenes, and mastering their application. Most are clinicians at heart. They continue to help clients on a daily basis in their own practices. They have hundreds of thousands of hours of shared experience, and their conclusions are based on real life, in the trenches experiences and observable outcomes. As a result, their ideas and approaches to treatment planning have direct relevance and application for you and your clients.

This book is a must have for your professional library. Whether you choose to explore the chapters in sequence or wander through the sections that interest you most, you will discover a world of ideas that will forever enrich your practice.

Eric Brown

Director of Bodyworkbiz.com



A Personal Note

I am a good friend and colleague to Erik Dalton – the mastermind behind this symposium – and I am thrilled to announce that he has finally compiled the book for which we have all been waiting. Within these pages, we are privy to the practical wisdom gained from years of hands-on experience, coupled with a passion for questioning the “norm.”

Here, innovative leaders ranging from physicists, psychologists, a human biologist, and an electrical engineer to movement specialists, instructors of physical therapy, and a professor of osteopathy/manual medicine introduce and share their journeys of bodywork excellence.

I have studied and exchanged ideas with several of the authors gathered here, including Robert Schleip, Serge Gracovetsky, Judith Aston, Art Riggs, Tom Myers, Til Luchau, Aline Newton, Adjo Zorn, Gil Hedley, and Dalton himself. And because of my experiences with each of them, I consider myself a better practitioner.

I first met Schleip when he came to study Rolfing® in Boulder, Colorado, more than 30 years ago. Since then, his research has become instrumental in providing scientific support for several of the theories that Dr. Ida Rolf proposed over 50 years ago. For example, Schleip has shown there are four nerve categories that innervate fascia, when for years, anatomy books posited only one.

Since seeing Serge Gracovetsky at the First International Congress on Low Back and Pelvic Pain in 1992, my teaching and private practice approach to low back pain has forever changed. In the early '70s, I was fortunate to take classes with Judith Aston, who was subsequently selected by Dr. Rolf to develop the first movement education course for the Institute.

Art Riggs has been writing books and teaching since 1988. I remember him as a bright student who plays a mean piano. As for Dalton, he is a workhorse who toils deep into the night due to his constant obsession with “never knowing enough.” He is more than a friend – he is an invaluable resource. As an “in the trenches” clinician, he is the colleague others turn to when we need to consult on challenging cases.

Dalton has an intuitive sense for translating complex theory and research into an understandable “hands-on” language, so readers can integrate these new and practical strategies into their practice. Dalton has used this skill in writing his chapters and compiling this book – a book I’m sure you’ll enjoy as much as I have.

Jim Asher

*Advanced Rolfing Instructor and founder of
the Colorado Cranial Institute*





Introduction

A former osteopathic instructor once told me, “Erik, if you ask any two clinicians to agree on one thing, the only thing they’ll have in common is the belief that a third clinician is doing it wrong.” That statement stuck with me for some reason, and after mulling it over, off and on, for the last few years, I’ve come to the disappointing conclusion that he was right. I’ve also come to the conclusion that it doesn’t need to be that way.

It’s not surprising that massage therapists, anatomists, structural integrators, chiropractors, yoga instructors, personal trainers, and research scientists would filter their views of the body through a philosophic lens, shaped by their individual experiences. Some approach pain and injury from a structural, postural, and biomechanic standpoint. Others elect to evaluate and treat pain using functional movement therapy. However, choosing a single approach to assessment and treatment – although convenient – can hinder our ability to best meet the needs of each client or patient.

A practitioner’s preferred approach may work quite well for one issue, yet this same approach can fall somewhat short when applied to a different client or condition. For other issues, the practitioner might find his or her preferred approach entirely ill-suited. Why?

Humans are not simple machines. Our myoskeletal system was not designed for the sole purpose of lugging around 30 feet of intestines, 60 miles of blood vessels, the heart, lungs, and sex organs. Our bodies were also made to express emotions, interact with others, and perform complex daily activities. Even the basic act of putting one foot in front of the other comprises a complex series of reactions, involving dozens of closely interrelated muscles, tendons, and bones, along with a vast network of fascia.

When we view our clients through a single lens, we may be tempted to stereotype the source of their pain, then treat the single offending body segment. What we must keep in mind is that the torso, pelvis, legs, and arms never act alone, but always in harmony with the rest of the body. A motion as simple as reaching forward to use this keyboard not only involves my hands and arms, but also my neck, back, pelvis, and abdomen. Even my feet come into play.

Decades ago, the legendary Dr. Vladimir Janda warned: “Keep in mind that the motor system functions as an entity and that in principle it is a wrong approach to try and understand impairments of different parts of the motor system separately without understanding the function of the motor system as a whole.”





Adding to the complexity of our profession – and perhaps sabotaging any hope of a single glorious cure-all approach to musculoskeletal issues – is the fact that no two clients are the same. Each body is a completely unique and complex machine. This is why attempts to apply the same solution to multiple clients – even when they present with seemingly identical symptoms – can fail.

With this book, I encourage readers to consider a more comprehensive and multidisciplinary approach to the human body. In your next client session, be aware of your assessment process. Are you only using one lens to determine proper treatment strategies for strengthening muscles, reducing pain, or improving flexibility? If so, consider viewing your client's body through any one of the diverse lenses presented here by our renowned contributors.

We have been fortunate enough to include lessons from some of the top practitioners and researchers in physical therapy, structural integration, osteopathy, chiropractic, and functional movement training. Within these pages, you'll find an intriguing flow of ideas regarding structure and functional movement, presented by Judith Aston, Adjo Zorn, Kai Hodeck, Craig Liebenson, and Serge Gracovetsky, and highlighted in chapters by Aline Newton, Til Luchau, and Robert Irvin.

Jerry Hesch introduces a new “two-minute” correction for SI joint dysfunction, along with collaborative evidence to support his recent sacral torsion findings. Gil Hedley's stimulating visual perspectives of fascial dissection are brought to life in Robert Schleip's chapter *Fascia as a Sensory Organ* and by Thomas Myers in his elegant *Anatomy Trains* model.

Four of the chapters I've written for this book take a deeper look at the pain and dysfunction that can develop through active hobbies, a certain fashion habit, and everyday movements. Two of the chapters focus on the common musculoskeletal issues associated with the popular pastimes of cycling and golf.

In *Well-Heeled*, we explore the negative impact of high-heels on posture and gait. Then, in a chapter titled *Human Silly Putty*, we consider how gravity and faulty movement patterns combine to effect chronic pain.

My fifth chapter concentrates on knee pain, addressing the confusion that often surrounds this complex joint, making it tough to determine the correct treatment plan. In each of these five chapters, I outline the appropriate steps to help restore proper function, beginning with an accurate assessment.





Art Riggs, in his contribution to the book, brings us up to date on the semantics of touch and new perspectives on pain, and James Waslaski's *Treating Tendinosis Conditions* offers practical applications for commonly seen injuries. A self-conditioning section featuring Aaron Mattes' *Active Isolated Stretching* and Robert Schleip and Divo Müller's *Fascial Fitness* closes the book.

These chapters reflect the expertise and individual “lens” of their respective authors – from background and style to approach and delivery. To best convey each author's voice and perspective, the *Dynamic Body* editors have intentionally avoided the trend to mold these chapters into one standard format.

Even with a tissue-based practice, the concept of using one form of therapy to treat every client who presents with a certain problem has not proven productive. A cookie-cutter model may work for baking, but not for the inherent complexities of human function and dysfunction. Instead of choosing one method over another, we encourage clinicians to incorporate a broad, multidisciplinary model that emphasizes a more holistic approach to rehabilitation.

There are many fine reference books that address basic principles and practice of manual and movement therapies, but this is one of the few books to present a global model for blending past, present, and future therapeutic approaches across multiple disciplines.

Erik Dalton, Ph.D.
Founder of Freedom From Pain Institute®





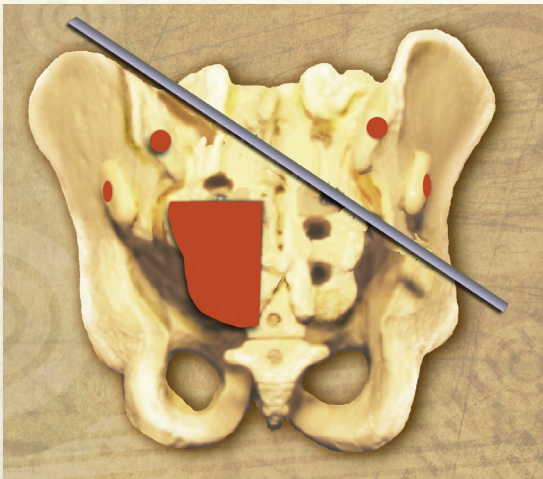
Jerry Hesch MHS, PT

For more than 30 years, Jerry Hesch has worked toward a three-dimensional understanding of joint movement. A licensed physical therapist, with a master's in health science, Hesch has meticulously examined existing research and literature for clinical problems without adequate solution – then worked to fill those gaps.

In doing so, he has developed an innovative approach to evaluation and treatment of joint dysfunction, known as the Hesch Method of Manual Therapy. Integration of the Hesch Method into practice helps the clinician swiftly and accurately pinpoint the exact nature of a client's joint dysfunction, to efficiently achieve strong clinical outcomes.

In July 2010, the Hesch Institute was established in Las Vegas, Nevada. This nonprofit organization aims to incorporate the Hesch Method into contemporary health-care practices, through initiatives ranging from research and education to clinical services and training.

For more information, visit <http://heschinstitute.org>.



***With torsion, one sacral quadrant will be prominent.
In the presence of a sacral torsion the sacrum will be most asymmetrical at only one side of the sacral base or apex. In the most common torsion, the left lower sacral quadrant is prominent.***

Sacral Torsion About an Oblique Axis

A New Approach to an Old Problem

Jerry Hesch, MHS, PT

*This chapter is an in-depth exploration of sacral torsion and sacroiliac joint dysfunction. It presents a model of nomenclature, evaluation, and treatment that is much more user-friendly than the traditional model. For those who do not want to dig deeply into the historical and theoretical reading, but do wish to learn the clinical application, you will find the latter part of the chapter that starts with **Torsion Evaluation** will suffice.*

Manual therapy applied to the sacroiliac joint (SIJ) encompasses a variety of types of movement dysfunction, and it may include a variety of pain presentations. In this chapter, SIJ dysfunction (SIJD) will be defined thus: Sacroiliac joint dysfunction is a movement dysfunction in which movement within the SIJ, or going through the SIJ, is altered, possibly causing pelvic posture to be altered and provoking proximal or distal pain. The pain may be intrinsic to the SIJ, or extrinsic – for example, from sacroiliac ligaments and other proximal soft tissue.

Due to the proximity of the lumbar and sacral nerve supply, pain patterns can be unclear. True SIJ pain is not always clearly demarcated. Furthermore, the SIJ and lumbar spine are inextricably linked and, therefore, I deny distinct and separate SIJD without lumbar segmental involvement. In contradistinction to much of the general literature, asymmetry is not a

necessary prerequisite for the definition of SIJD, as symmetrical and treatable hypomobilities and hypermobilities do exist.

A frequently reported sacral movement dysfunction is named “sacral torsion about an oblique axis,” which is also known as “sacral torsion,” or simply as a “torsion.”^{1,2} Torsions do meet the above definition of SIJD, and they are the focus of this chapter. I also include my method of evaluation and treatment for sacral torsions.

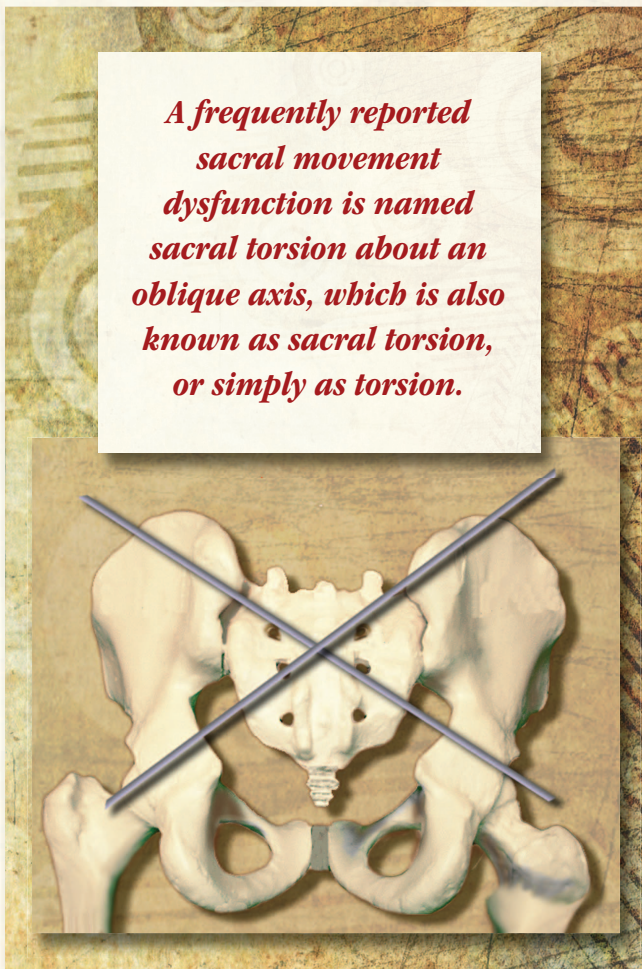
There are other axes and other types of sacral dysfunction that will not be detailed in this chapter. These include forward-bending and backward-bending restriction, pure rotation on a vertical axis, pure side-bending, and posterior glide.

Some patterns that might be predicted do not actually appear to exist, or are extremely

rare, such as anterior glide, side-glide, and dorsal plane tilt (imagine a pinwheel axis to differentiate from side-bending).

My work is a distinct enhancement from the traditional evaluation and treatment paradigm, and is, therefore, referred to as the *Hesch Method*.

A frequently reported sacral movement dysfunction is named sacral torsion about an oblique axis, which is also known as sacral torsion, or simply as torsion.



Torsion Theory

A sacral torsion is a pattern of traumatic, symptomatic, sacral asymmetry with altered movement in the SIJ and lumbosacral joints. It is described in many works on osteopathic-based biomechanics of the SIJ³⁻⁸ and also in some physical therapy texts.^{9,10} Typical works on manual medicine, manual therapy, and muscle energy technique (MET) often address SIJD and torsion.

In the SIJ, torsion is a type of dysfunction in which the sacrum is described as becoming stuck while moving within the ilia about the left or right physiologic oblique axes (Fig. 1).^{10,11} Therefore, torsion can also appropriately be referenced as a sacral “fixation or restriction.” There are a total of four types of torsion: Left on Left, Right on Right, Right on Left, and Left on Right, oftentimes abbreviated as L on L, R on R, R on L, L on R. The nomenclature will be addressed in detail later in the chapter.

Torsion might be an un-physiological dysfunction

It may seem counterintuitive and somewhat paradoxical, but the sacrum can actually go further into the direction of fixation. However, it cannot move back to physiological neutral or beyond it into the opposite direction without a corrective maneuver.

This phenomenon is explained as obeying the *Rule of Physiological Motion* (dysfunction).

The rule defines physiological motions as those motions that are normal based on the design of the structure. For example, the knee primarily flexes and extends and slightly rotates during gait, and these are *physiological motions*. A lateral blow to the knee induces a valgus movement which is *un-physiological*.

In spite of the fact that torsions obey this rule, I believe they are not a normative physiological motion, such as part of the gait cycle, per osteopathic theory as described by Dr. Philip E. Greenman,¹² former professor of osteopathic manipulative medicine, as well as physical medicine and rehabilitation, at the Michigan State University College of Osteopathic Medicine, and in most other works on the subject. Rather, it takes a large passive, extrinsic force, in addition to vulnerable positioning, to induce torsional movements and fixations – for example, lifting a heavy object with the spine in full flexion, rotation, and side-bending.

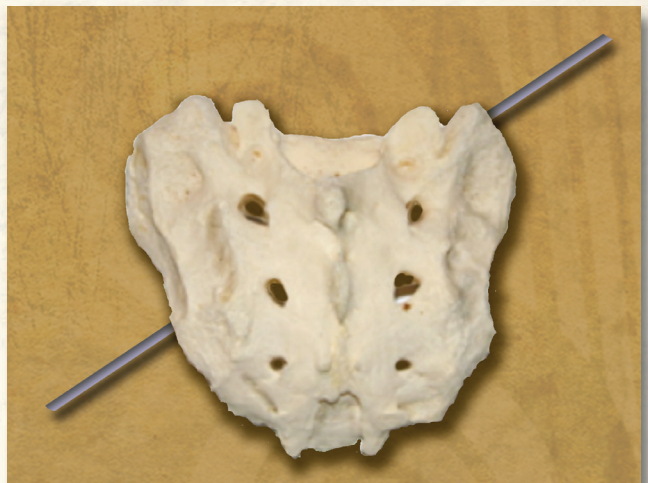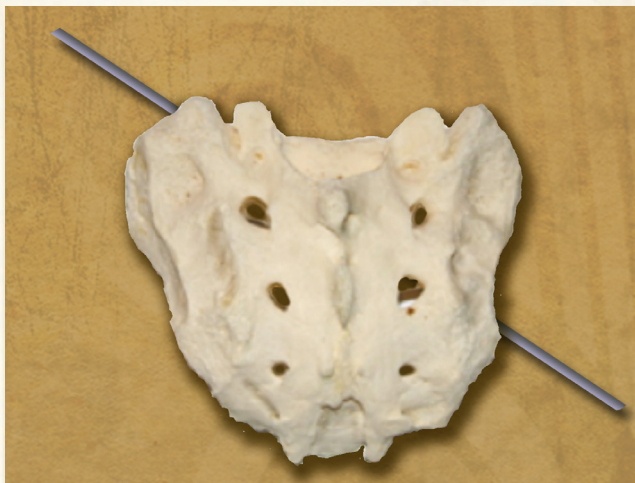


Figure 1: The left and right oblique axes of the sacrum. The left oblique axis originates above the left side of the sacrum, whereas the right oblique axis originates above the right side of the sacrum.

Torsion theory often absent in movement science textbooks

It is noteworthy that the concept of torsion is either trivialized, without justification, or completely omitted in several traditional works and in contemporary works on manual therapy, including physical therapy and sports medicine literature.¹³⁻²² Although torsion may be absent or minimized, these works do address the general concept of SIJD.

A few manual medicine practitioners, such as Dr. John F. Bourdillon²³ and Dr. Karel Lewit,²⁴ do not endorse a torsion model. Also, a remarkably detailed textbook on joints, *Joint Structure & Function: A Comprehensive Analysis*, briefly covers the SIJ in less than four pages, but avoids sacral torsions.²⁵ Another thorough textbook, *Kinesiology of the Musculoskeletal System: Foundations for Physical Rehabilitation*, also limits explanation of sacral motion to nutation and counter nutation.²⁶ The topic of sacral motion is limited to a single page.

Both these textbooks hold a prominent location in my library. If published clinical and basic science studies existed that showed the validity of torsion motion, and utility of treatment for torsion, I believe that these very thorough texts would then appropriately expand the sections on sacral mechanics. This knowledge gap is a valid clarion call for novel research.

Both the above textbooks have an especially strong and relevant explanation of the relationship of the pelvis to the hip and lumbar spine, and the reverse thereof. This description is welcomed by clinicians who perceive pelvic pathomechanics as distinctly different from SIJ movement dysfunction.

Donald A. Neumann, professor of physical therapy at Marquette University, clearly states the problem of the SIJ concept in physical therapy: "Adding to the clinical ambiguity of the sacroiliac is the lack of standard terminology to describe the related anatomy and kinesiology. As a result, the biomechanical and clinical importance of the SIJ is often understated or exaggerated."²⁷

Torsions frequently coexist with low back pain, making them difficult to isolate as the underlying issue.

Torsion theory is evolving

SIJDs can be difficult to diagnose, which can lead to confusion among practitioners. Some who acknowledge SIJD have even begun to doubt the very existence of sacral torsions. Torsions frequently coexist with low back pain, making them difficult to isolate as the underlying issue. Proximal spasm and postural aberration can give the appearance of a primary lumbar or lumbosacral dysfunction, whereas any occulted torsion will be more apparent in a fully flexed posture.

On the other hand, many clients are misdiagnosed with SIJD when they are actually experiencing spasms or shortened soft tissues. These tissues can impact the posture and movement of the entire pel-

vis, hip, and lumbar spine. However, these asymmetries of posture and movement do not necessarily equate to a faulty fixation within the true SIJ.^{28,29}

Two authors make noteworthy contributions to torsion theory in contrast to most writings, which simply reiterate the traditional theory and treatment without much debate. Osteopathic physician Dr. Myron C. Beal questioned the entire concept of torsions quite some time ago,³⁰ while another

This chapter will present an alternate model of sacral torsion theory.

osteopathic physician, Dr. Theodore R. Jordan, suggests replacing the joint fixation model with a soft tissue asymmetry model, based on the segmented innervation of the multifidi muscles.³¹

In contrast to Beal and Jordan, I believe that torsion is, in fact, a valid movement dysfunction of the SIJ, and that the lumbosacral facet motion is also altered. I believe this motion is significantly restricted, such that “lumbosacral-sacroiliac joint torsion” might be much more accurate than “sacroiliac torsion.”

This complex pattern is worthy of being understood and applied, as opposed to being avoided completely. Unfortunately, as we have seen, SIJD, and especially torsions, tend to be esoteric for the majority. Therefore, more research is required to make SIJD diagnoses more accurate.

In his text *Principles of Manual Medicine*, Greenman summarized the challenge of the torsion concept with this statement: “Fortunately, biomechanical research into the pelvic girdle is increasing, and as

new knowledge is acquired, the theoretical construct provided here may well need modification. Though the exact biomechanics of the torsional movements of the sacrum are unknown, the hypothetical left and right oblique axes are useful for descriptive purposes.”³²

This chapter will present an alternate model of sacral torsion theory, along with an evaluation and treatment model that appears to be more user-friendly than the traditional protocol. In spite of controversy regarding SIJD in general,³³⁻³⁶ for me, evaluation and treatment have both personal and clinical utility.

The goal of this chapter is to share novel concepts regarding torsion within the overall topic of SIJD. By the end of the chapter, the reader should be able to name the four types of torsions using a clear and simple nomenclature, as well as effectively evaluate and treat them with a novel method. Torsions are complex for a number of reasons, which we will now explore.





Figure 2: A square lettered block in neutral and in torsion about oblique axis. The square block is easy to visualize at rest due to the symmetry of each face. When torsioned about an oblique axis, it is still easy to visualize. This object readily retains the original frame of reference, meaning it is still easily identified as a square lettered block.

Torsion is difficult to visualize


Several clinicians note that torsions present visual complexity. Physical therapist Allyn L. Woerman³⁷ asserts, “sacral torsions are perhaps the hardest dysfunction to conceptualize,” which I readily affirm. Sacral torsion is a tri-plane movement dysfunction of the sacrum about an oblique axis. The axes are tri-planar, therefore, the motions about the axes are complex and difficult to visualize.

The primary motion is left or right rotation, occurring in the transverse plane. Sagittal plane flexion and extension and frontal plane side-bending are all lesser torsion motions. Flexion/extension and rotation are additive, such that the most obvious asymmetry of the sacrum will be that one sacral quadrant is


notably posterior to the other three quadrants. The side-bending component is discernible, although more subtle.

In any given anatomical structure, three-dimensional biomechanics are both complex and challenging to visualize. In fact, the majority of clinicians typically evaluate motion one plane at a time. Perhaps a square lettered block, a child’s educational toy that is symmetrical at rest, is somewhat easier to visualize as making a positional change along an oblique axis (Fig. 2).


However, it is not as simple to visualize a structure as complex as the sacrum having 3-D motion. Figure 3 shows the sacrum in neutral rest position and in a position of torsion.




A. Neutral position




B. Right rotation on left oblique axis



C. Left rotation on left oblique axis



D. Right rotation on right oblique axis



E. Left rotation on right oblique axis

Figure 3: These images show the sacrum in neutral (A) and in each of the four torsion positions (B-E). The sacrum is a more complex structure than the block seen in Figure 2. The three-dimensional complexity of the sacrum does not require elaboration. For ease of visualization, a simplistic graphic representation is provided.

When a diagram demonstrates both axes together (Fig. 4), I find it even more difficult to interpret.^a The complexity of sacral torsion will be elaborated on throughout this chapter. Now, we will explore the semantic challenges of torsion.

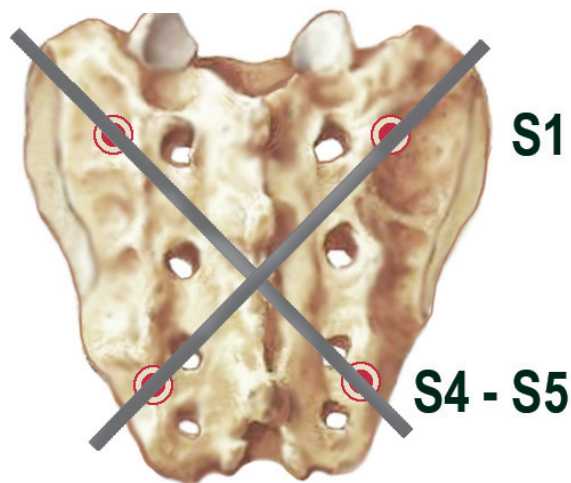
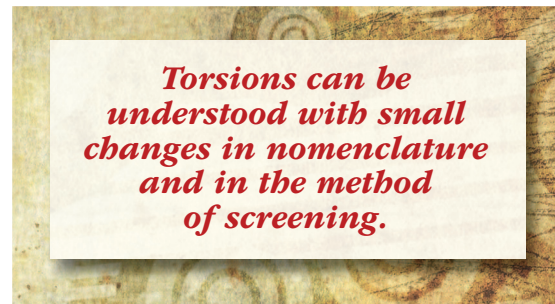


Figure 4: This is the **sacrum with both oblique axes shown together**. Showing both left and right oblique axes together adds another layer of complexity, in contrast to showing one axis at a time.

Torsion terminology is problematic

Osteopathic physician Dr. Daniel D. Janiak informs us that: “Confusion in terminology occurs because there are numerous synonyms for terms, several models or systems of nomenclature used to define the biomechanics observed, different criteria describing dysfunctions in different systems, and several ways of naming dysfunctions.”³⁸

One osteopathic list of terminology contains more than a dozen different names for sacral torsions and their categories.³⁹ I will make the assumption that the term “categories” is used here to describe variations, such as sacral shear and unilateral flexion/extension, which are not pure torsions. For clarity, I removed these two types from this list and will comment on them specifically later in this chapter.



These terms on the list are: sacral torsion, anterior sacrum unilateral (Strachan model), posterior sacrum unilateral, backward torsion, left on left torsion, left on right torsion, right on right torsion, right on left torsion, and forward torsion. Some of the definitions that follow these terms, including those encountered in other works, are at times vague and imprecise, lacking in sufficient detail. Hence, any errors I make here are my own and are unintentional.

The complexity of the four types of torsions – L on L, L on R, R on R, R on L – is actually eclipsed by another category of sacral dysfunctions, called unilateral flexion and unilateral extension. It is counterintuitive and frustrating to have only a few landmarks for palpation, coupled with a few gross motion tests (macro-motions of spine and pelvis), which then lead to a complex biomechanical diagnosis with very confusing terminology.

Dysfunctions, such as unilateral sacral flexion and extension, truly seem untenable, as one has to imagine that the sacrum flexes/extends on one side only, which it surely cannot. How is it possible that a solid structure such as the sacrum can flex or extend on one side only?

The unilateral flexion/extension model seems irrelevant after utilizing a few more landmarks for palpation and visualization, and adding passive spring/micro-motion tests. Right or wrong, I interpret unilateral flexion/extension to be the same as torsion, except that the direction of side-bending is opposite of what it would otherwise be, for any of the four torsions.

Now *that*, if true, is extremely difficult to visualize and accept as possible, except perhaps in cases of

^a Sometimes, the two oblique axes are also shown together with the two hypothetical transverse axes, which I defer demonstrating due to unnecessary complexity. Another SIJD, posterior glide of the sacrum, does not appear in many works on SIJD, and the A-P axis is, therefore, rarely encountered. This axis would also allow pure side-bending, which is rare, if valid. This is also true for the pure vertical axis, which would allow pure left and right sacral rotation. I previously espoused this pure rotation as more common than oblique axis torsions, but I now believe it is not a true joint rotation, but rather a unilateral spasm that blocks motion transferring through the sacrum. It looks like a rotation and altered ligament tone is present due to muscular attachments to SIJ ligaments, a concept that is not expressly addressed in detail in most works on SIJD.

profound instability, such as fracture and dislocation. In three decades, I have never encountered a unilateral flexion/extension of the sacrum, though I have searched in earnest. This search utilized additional landmarks, multiple passive spring/micro-motion tests with the spine and pelvis in neutral, end-range flexion and extension, in addition to the traditional screen.

Sacral shears are also a variant of torsions, and like the unilateral flexion/extensions, they are so similar as to create difficulty in conceptualizing them. I will defer elaboration on shears as the same reasoning applies to them as the unilateral flexion/extensions. Torsions do share a similar, albeit lesser complexity. Ultimately, however, torsions can be understood with small changes in nomenclature and in the method of screening.

Torsion nomenclature should be changed for clarity

I submit that clarity can be established with minor changes in the torsion nomenclature. One suggestion is to avoid the abbreviated terms, such as L on L or left on left, R on R or right on right, as they do not convey enough information. The formal, traditional terms should be used, such as left torsion on left axis. These phrases can be further clarified by stating that the axis is an *oblique* axis, as in “left torsion on left *oblique* axis,” which does appear in the literature, although not consistently.

Completely replacing the term “torsion” with “rotation” is congruent with terminology used at nearly all other joints in the body. For example, “left *rotation* on left oblique axis.” Lastly, an additional enhancement can be made by reminding the clinician that the upper origination of the axis will denote whether it is a left or right axis. Adding the term *upper* to the axis can be clarifying, such as “right rotation on *upper* left oblique axis.” Further simplification, which, in my opinion, adds semantic clarity, is described below.

Compare and contrast the new nomenclature below with the traditional naming schema. The comparison is enhanced in Table 1, which also lists position and spring/micro-motion test results. The new nomenclature seems much easier to visualize and

understand, and the specific treatment required is implied within the definition.

Specifically, the therapeutic mobilizing force is applied to the prominent and blocked sacral quadrant. The palpation and spring/micro-motion test findings also seem much easier to communicate from one clinician to another.

The following terminology is suggested as the most ideal improvement over the traditional.

- 1** *Posterior left lower sacral quadrant with blocked P-A spring, instead of left on left sacral torsion, or left rotation on left upper oblique axis.*
- 2** *Posterior left upper sacral quadrant with blocked P-A spring, instead of left on right sacral torsion, or left rotation on right upper oblique axis.*
- 3** *Posterior right upper sacral quadrant with blocked P-A spring, instead of right on left sacral torsion, or right rotation on left upper oblique axis.*
- 4** *Posterior right lower sacral quadrant with blocked P-A spring, instead of right on right sacral torsion, or right rotation on right upper oblique axis.*

	POSITION			MOBILITY		
NEW NOMENCLATURE <i>Traditional Nomenclature</i>	Upper Sacral Quadrant	Lower Sacral Quadrant	*Sacral Inferior Lateral Angle (ILA)	Sacral P-A Spring Above Oblique Axis	Sacral P-A Spring Below Oblique Axis	*Superior Spring to Sacral ILA
Posterior Left Lower Sacral Quadrant With Blocked P-A Spring <i>(Left Rotation on Left Oblique Axis)</i>	subtle, n/a	posterior left	inferior right	mobile right upper quadrant	restricted left lower quadrant	restricted right
Posterior Right Lower Sacral Quadrant With Blocked P-A Spring <i>(Right Rotation on Right Oblique Axis)</i>	subtle, n/a	posterior right	inferior left	mobile left upper quadrant	restricted right lower quadrant	restricted left
Posterior Left Upper Sacral Quadrant With Blocked P-A Spring <i>(Left Rotation on Right Oblique Axis)</i>	posterior left	subtle, n/a	inferior right	restricted left upper quadrant	mobile right lower quadrant	restricted right
Posterior Right Upper Sacral Quadrant With Blocked P-A Spring <i>(Right Rotation on Left Oblique Axis)</i>	posterior right	subtle, n/a	inferior left	restricted right upper quadrant	mobile left lower quadrant	restricted left

Table 1: This table shows the **four lumbosacral-sacroiliac torsions with new nomenclature** and traditional sacral torsion nomenclature. Lumbosacral is a term that reminds the reader that the lumbosacral facets are part of the torsion SIJD. On the left column the new terminology is contrasted with the traditional. Across the top row, the palpatory and spring/micro-motion test findings are addressed, while the gross/macro-motion tests from the traditional evaluation model are not, because the spring/micro-motion tests are, by their very nature, much more precise. *These are only included for the sake of completeness. As stated in this chapter, it is not necessary to screen the superior/inferior position and mobility of the ILAs, as these components resolve when the primary rotation is corrected.

Another significant shift in general nomenclature would be to lucidly demarcate the SIJ and the bony pelvis. The bony pelvis and the SIJ are not one and the same, and their distinctions should not be blurred. This is of paramount relevance. In spite of using biomechanical terminology of the SIJ, clinicians are often inadvertently describing movement dysfunction of the entire pelvis, which couples with the hips and trunk. A person who has a solid, bilateral fusion of the SIJ can only have movement of the bony pelvis. These individuals can still have asymmetries with the traditional palpation and gross/macro-motion tests – a significant example of false-positive tests.

Surely, a change in semantic and biomechanical theory is mandated for asymmetries within this population. In fact, this suggestion applies to all patient populations. Dropping the term *sacroiliac joint dysfunction* and replacing it with *lumbopelvic-hip dysfunction* is reasonable and congruent with the prevailing research whenever one is describing asymmetry of pelvic landmarks or asymmetry of motion palpation (traditional tests).

Unfortunately, many well-meaning clinicians perpetuate inaccuracy, stating observations such as “*your pelvis (or sacroiliac or hip) is out,*” and so on. Asymmetry of the pelvis does not equate with joint fixation of the SIJ, and balancing the pelvis in static and dynamic traditional SIJ contexts does not mean that the SIJ was “manipulated, adjusted, or corrected.” However, many clinicians naively embrace this belief system and abandon other explanations. This statement cannot be adequately emphasized.

The SIJ and bony pelvis are sometimes properly treated together. Other times they are treated individually. When treated collectively, the term “lumbopelvic-hip complex” is appropriate.

The use of the term “lumbopelvic” has recently provoked some heated debate, and perhaps it will continue to be on the radar of manual therapists and passionate clinicians.^{40,41}

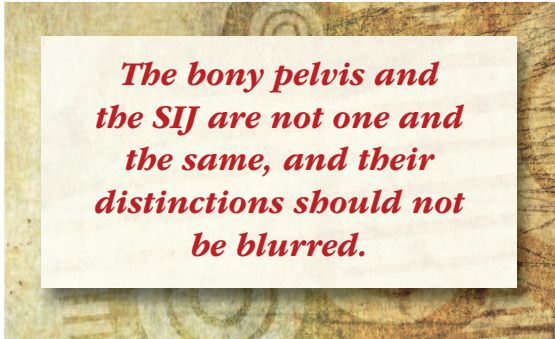
Three recent articles use the term “lumbopelvic” in the title or the body text, which indicates that the term is probably here to stay, regardless of any controversy.⁴²⁻⁴⁴ Many more can be encountered, using a PubMed.gov Internet search, which span a spectrum of disciplines, even when one limits the search to 2010 and 2011.

“Spinopelvic” is another proximal semantic term encountered in the search. Evaluating and treating pathomechanics of the pelvis as separate and distinct with regards to the SIJ should be a normative practice for

any and all biomechanically based clinicians. The creative clinician needs to bridge the two topics of so-called SIJD and pathomechanics of the pelvis – a separate, albeit linked, phenomenon.

The bony pelvis can move in three-dimensional space, independent of the SIJ, which means that SIJ motion does not necessarily occur with normative pelvic motions, at least not until very end-range postures.^b This distinction is so fundamental that the pelvic mechanics are addressed in nearly all works on hip and on gait mechanics. The pelvis has a relationship with the hip below and the trunk above, so that biomechanical dysfunction of one is clinically relevant to the other.

Unfortunately, there are distinct limits in the body of literature with respect to clinical intervention directed at specifically restoring normative biomechanics of the bony pelvis, as opposed to the many interventions directed at the SIJ, hip, extremity, and trunk. There seems to be an



The bony pelvis and the SIJ are not one and the same, and their distinctions should not be blurred.

^b This can seem very unintuitive for those who have been exposed to SIJD. While the sacrum may, in fact, forward-bend about a transverse axis upon arising, such as supine to sit to stand, it does not continue to move during gait and normal ADLs. Rather, it compresses, then acts as a moving three-dimensional force transducer. Try this as a demonstration: Place a fist inside the other hand with full contact to represent the compression. Now, keep them locked and move them about in multiple directions. The concept will become self-evident.

unspoken belief that directly restoring hip function translates to restored pelvic function, and this I have found to be untrue at times.

I find it necessary to specifically apply a fulcrum with mild force for five minutes to improve or restore pelvic pathomechanics, such as side-glide, anterior and posterior glide, transverse plane rotation, and so on. Treating the other aforementioned structures does not attain the same results.

My work includes a novel treatment method directed at restoring normal mechanics of the bony pelvis, and separately, a novel treatment method for SIJD, within a whole-body intervention. The term “bony pelvis” is used to speak only of motion of the entire pelvis, in the absence of concomitant SIJ motion. In my community, one can readily encounter the elderly who have had a hip or knee replacement, yet still ambulate with a (treatable) pelvic side-glide fixation. Their pelvises are off-set to one side, in stance and during gait.

This is most likely a residual preoperative strategy for pain reduction through reduced unilateral

weight-bearing, which remains as a non-functional postoperative pattern. This dysfunction is unfortunate, and a reasonable conclusion would be that the mechanics of the pelvis are inadequately treated during postoperative hip and knee rehabilitation.

I believe that an intervention, such as the Hesch Method, for this population would be highly appropriate, for the purpose of preventing or minimizing wear and tear on joints in the lower half of the body. In fact, treating this side-glide, if it is present, is one of the first things I do when treating any type of SIJD. Sometimes, it is too subtle to be observed, and I always screen for it with passive spring/micro-motion tests, regardless of whether or not I suspect it to be present.

In summary, the hope is that precise biomechanical nomenclature will encourage optimal treatment by addressing the correct singular or interrelated structures. Treatment techniques are not static, but rather evolve with improved basic science and clinical science.





Figure 5: Here we see a matchbox with an oblique axis. Although a matchbox is sometimes used to represent a sacrum in continuing education classes and writings, it is a very inadequate representation, further adding to confusion. In the photo on the right, the image has rotated about the oblique axis so that the left lower quadrant is, in fact, the most prominent one. However, the side-bending component cannot be visualized, as it is completely absent. Mentally translating this matchbox image to that of a sacrum is problematic to the image of a sacrum.

Inadequate Teaching Methods

Multiple formal and informal surveys from 2001 through the present indicate that torsion nomenclature and teaching methods are apparently inadequate.⁴⁵ In spite of exposure to torsion theory and application from several sources, few physical therapists go on to evaluate and treat torsions in their daily clinical practice. This confusion regarding nomenclature and clinical application happens even though the majority of the survey takers had previous exposure to torsion concepts through their professional education, continuing education, and clinical exposure.

Unfortunately, torsion theory and treatment fails many physical therapists, whether they have bachelor's, master's, or clinical doctorate and Ph.D. degrees. Fortunately, those who take my seminar find the concepts much easier to grasp due to the use of clearer language, breaking up the sacrum into four quadrants and explaining that motion will be blocked in one quadrant for each type of torsion.

By deferring focus on the axis and explaining that the side-bending component will resolve by addressing the stuck quadrant (rotation), students readily grasp the concept. Treatment is simple, straightforward, and logical. Feedback tallied from the last two seminars (June and July 2011) showed that before the seminar, 10 percent of the students indicated they could effectively treat torsions. This number increased to 94 percent after the seminar.

I have taken various classes in physical therapy and manual therapy, which included topics such as muscle energy technique (MET), strain/counter strain, massage, orthobionomy, positional release, and other forms of mobilization and manipulation. In many of these classes that addressed sacral torsion, participants were given a matchbook with an inscribed axis, as a tool to visualize torsion. The instructor would ask us to imagine that *"this matchbook is a sacrum moving on an oblique axis,"* as pictured in Figure 5. This matchbook teaching has shown up in

a very comprehensive lumbopelvic-hip chapter, and can probably be found in other texts as well.^{10,46}

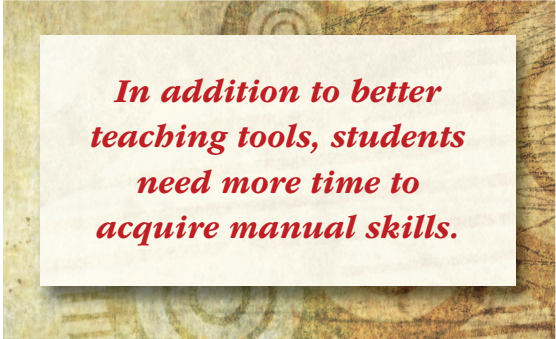
Surely, a matchbook does not have any resemblance to a sacrum in the frontal, sagittal, and transverse planes. A simple solution is readily available – purchasing inexpensive sacral models or flexible pelvic models.^c Wires from metal coat hangers, cut in four-inch lengths, dowels, or pencils are useful for representing the physical axes. For decades, I used these sacral anatomical models with tangible axes.

The seminar participants and I have found this method helps immensely in developing the skill of visualizing torsions. Physically moving the sacrum on the physical axis is more lucid, tangible, and visually accurate.

In addition to better teaching tools, students need more time to acquire manual skills. This additional investment in hands-on education would help ensure that skill sets become more consistent among practitioners. Post-course surveys indicate that we can improve our traditional evaluation and treatment model so the majority of clinicians become comfortable with sacral torsions.

True clinical knowledge is reflected in behavior. If a technique is not easily understood and utilized, it may fall off the radar of contemporary topics worthy of research. My hope is that torsion research will be encouraged as more educators and clinicians better understand the subject matter. Research will determine the degree of utility, validity, inter- and intra-rater reliability, sensitivity, and specificity as they relate to evaluation and treatment.

Not only is the theoretical model a challenge to understand, but the traditional treatment methods are rather complex as well, which is our next topic in this chapter.



In addition to better teaching tools, students need more time to acquire manual skills.

Treatment is unnecessarily complex

The treatment technique for torsion can be rather complex. **The following is a typical treatment sequence for a left on left sacral torsion, using muscle energy technique.**⁴⁷

1. *Patient in left lateral Sims position, close to edge of table, right arm over side of table, left arm behind and on table.*
2. *Operator faces patient, palpates lumbosacral junction.*
3. *Operator flexes patient's legs (knees and feet together) until motion felt at sacral side of L5 junction.*
4. *Patient's legs maintained in this position against operator's abdomen, hip, or thigh.*
5. *Operator's right hand now moved to patient's right shoulder. As patient exhales, instructed to reach to floor with right hand. Operator maintains pressure on right shoulder. Repeat until L5 is rotated to left.*
6. *Operator's left hand moves to patient's feet, which are placed off edge of table, and pressed downward.*
7. *Patient instructed to push feet to ceiling as operator maintains pressure on patient's feet and monitors L5 junction.*
8. *When patient relaxes, slack is taken up by operator with left hand.*
9. *Repeat step seven two or three times. (Right sacral base should be felt to move posteriorly.)*
10. *Retest! Note: A variation allows the operator to sit on the table with the left hand monitoring the sacral base, while the right hand resists elevation of patient's legs toward ceiling.*

I find the above positioning to be a challenge for both patient and practitioner. Theoretically, it seems possible that these positions and forces could challenge acute clients in severe pain and could place a pathological disc at risk. In spite of four photos to accompany the above text, the positioning and treatment method is, for me, quite challenging. I have never incorporated it into my care. Instead, I developed a model of torsion evaluation and treatment that made sense to me, one that I could apply on a daily basis with much simpler and direct force application.

During a time of medical disability, I needed to develop a treatment method that used short levers with small forces, as opposed to the challenging techniques that were hard on my body. The treatment techniques I developed are easy to understand and apply, as are the self-treatments, which will be presented at the end of the chapter. For now, we will move on to review research on sacral torsion, as well as general SIJD.



SIJ and Torsion Research

Torsion research is limited

Torsions are nearly always described as being a normal motion that occurs during the gait cycle, but this concept has been indirectly discouraged by some clinicians and educators, who essentially dismiss the overall validity of the clinical concept of SIJD, except in females – during the peri-partum state and with hormonal cycles.^{36,48,49}

The general disbelief in SIJD is based several factors, such as a lack of validation in imaging and anatomical studies, very limited motion in the joint in the average person, and many studies that report limited inter-examiner reliability of position tests and gross/macro-motion tests.⁵⁰⁻⁵² These studies also reference controversy with a limited number of viable pain provocative tests described by other researchers.^{53,54}

Specific tissue isolation with these pain provocation

tests has not been identified, and some of the force traverses the hip, the SIJ, and the lower lumbar spine and lumbosacral junction. These tests, when positive as a cluster (not singularly), do correlate with a positive response to SIJ injection.

A valid concern with this pain-provocation model is that, in spite of the fact that many clients have lumbopelvic asymmetries, the majority have negative pain tests, and treatment should not be avoided based on these negative pain tests, especially with respect to the philosophy of wellness and prevention, and on regional interdependence of somatic structures.

It is noteworthy that there are no imaging studies to validate or negate the theory that torsion motion occurs during gait. Though many clinicians who treat the SIJ accept this torsion-gait model as fact, it may be that the sacrum does *not* move in torsion during gait, at least not to the degree that it can be discerned by simple palpation motion testing. Palpation will discern altered muscle tone, or pelvic asymmetry with gross/macro-motion tests, which may be misinterpreted as sacral motion. It is reasonable and timely that the theoretical construct of torsions is being challenged.

Not a single *clinical* torsion article was encountered using a PubMed search (September 27, 2011) with key words “sacral torsion.” Yet, there is an abundance of basic science *in vivo* and *in vitro* studies that demonstrate torsional motion and torsional forces through the pelvis and SIJ.⁵⁵⁻⁶⁵

One author presents detailed reviews of the literature and describes how he performs torsion mobilization on patients.^{66,67} A single photo showing manual contact on the sacrum appears to demonstrate a rotational and side-bending force application. The description was rather general, stating: “This movement restriction was reversible, as manual treatment in accordance with the biomechanics of these joints could restore the normal motion.”⁶⁸

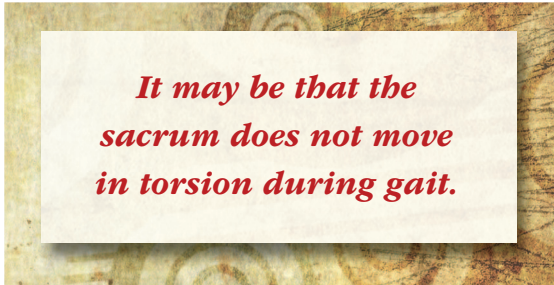
Osteopathic physician Dr. Fred L. Mitchell informs us that the torsion concept was well-established in the osteopathic profession prior to 1958, with some seminal work on this concept performed in the 1940s by osteopathic physician Dr. Harold Magoun and

others.⁶⁹ It is noteworthy that sacral torsion has not undergone a conclusive clinical outcomes study per the PubMed search using the key phrase “sacral torsion.”

Imaging studies of clients who present with torsions are needed to contrast pre- and post-intervention findings. Evolution of the torsion paradigm will happen with time, energy, research, education, clinical funding, and – most importantly – professional commitment. Although articles on theory and technique exist, there is a significant knowledge gap regarding the clinical benefit

of torsion therapy, and published studies are very much in need.

In the next two sections, we will look at some research that is being used to discourage general SIJ treatment, as well as some published works that encourage treatment for SIJD.



It may be that the sacrum does not move in torsion during gait.

Some research discourages SIJ treatment

Several prominent motion studies appear in works that strive to negate the SIJD concept. Research by Dr. Niels Egund and, separately, Dr. Bengt Sturesson describe an average of less than two millimeters of SIJ glide and less than two degrees of rotation.⁷⁰⁻⁷² These studies looked at several end-range postures and the standing hip flexion SIJ test. To perform the test, the posterior superior iliac spines (PSISs) are palpated, with the client standing and flexing one hip to 90 degrees and back to neutral, then repeating it on the other side. Asymmetrical total excursion is purported to indicate a motion dysfunction of the SIJ.

Sturesson effectively negated the basic premise of the standing hip flexion test. This is not a true SIJ movement test – it primarily measures movement of the entire pelvis on the contralateral femoral head, not of the SIJ. Thus, any trunk, pelvic, or lower extremity muscle or joint or movement strategy imbalance could adversely affect the test.^{28,73}

The Egund and Sturesson motion studies are frequently cited by clinicians and authors who discourage clinical intervention for SIJD, based on

the opinion that the minimal motion in the SIJ may not be perceived by most clinicians. These studies may be over-interpreted, however, as they do not take into account the fact that the SIJ lies deep within the pelvis, and that positional and spring/micro-motion tests have a leverage effect because they act at a distance. Therefore, small motions will be amplified.

A two-millimeter glide dysfunction in one ilium, an opposite directional glide in the opposite ilium, and a two-millimeter glide in the symphysis pubis are additive, and one can do the same with two degrees of rotation at each of the three joints. The concept is worthy of consideration, regarding motion perceived through passive tests, but not with gross/macro-motion, such as the standing hip flexion test.

There is one caveat: It is a fundamental principle that when motion is taken up in one direction, such as in flexion, there is a concomitant reduction in available side-bending and rotation, and predictive quantification is difficult.

Rather than use this data to discourage evaluation of the pelvis and SIJ, it is my belief that we need to re-evaluate the manner in which evaluation it is taught. Inter-tester reliability may improve if more time is spent teaching this important part of a thorough musculoskeletal evaluation. Repetition throughout the educational process is also a relevant consideration, It is supported by greater inter-tester reliability among clinicians with three to five years of experience, in comparison to those with six months of experience.⁷⁴

Research on the Hesch Method concluded that seven of 10 passive spring/micro-motion tests and 12 of 15 positional tests demonstrated clinical usefulness of 70 percent or greater inter-tester agreement, and no single test had less than 60 percent agreement.^{75,76} Hesch Method evaluates passive motion in non-weight-bearing contexts, such that the upright compressive and ligamentous forces, described by Sturesson as limiting SIJ mobility, are significantly reduced.

The form and force closure effect on the joint stability in upright posture are significantly reduced when spring/micro-motion tests are performed in supine, prone, and side-lying, which determines the *unloaded behavior* of the structure.

The spring/micro-motion tests have a much greater utility than the traditional movement tests in isolating the SIJ. These spring/micro-motion tests are simply an enhancement to the standard orthopedic manual physical therapy tests performed in all other joints in the body.

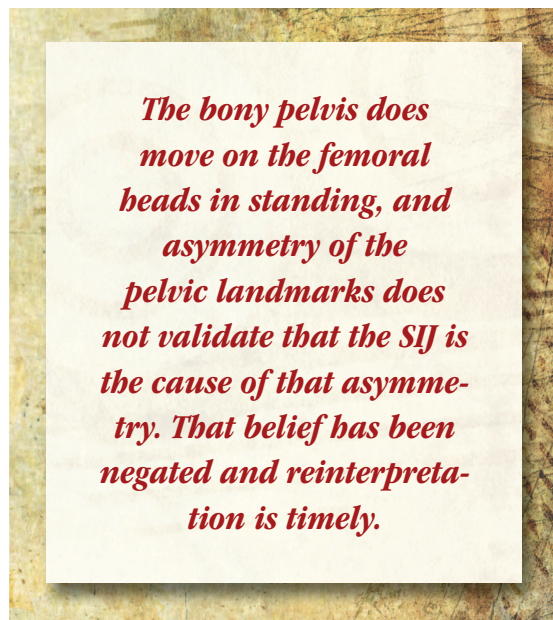
It is worth noting that Egund's and Sturesson's studies demonstrated motions at or near end-range positions of the trunk and limbs. I submit that forces go through the joint during the gait cycle, but that these forces are compressive, as opposed to torsional, and

true motion, such as sacrum moving on the ilia, happens only at end-range. This hypothesis is worthy of further inquiry.

Sturesson explained that, on the weight-bearing side, SIJ mobility would be considerably restricted through compressive form (joint shape stability) and force closure (external muscle and ligament effect on stability), and that ligamentous tightening would also restrict motion contralaterally. Egund's and Sturesson's studies conflict significantly with other motion studies that use magnetic markers on external pelvic bony landmarks and show significantly greater SIJ motion.⁷⁷⁻⁸⁰

The studies using magnetic markers correlate with palpatory motions in revealing significant motion of *extra-articular* landmarks – specifically, the bony pelvis. In contrast, Egund's and Sturesson's studies evaluate true *intra-articular* motion. The bony pelvis does move on the femoral heads in standing, and asymmetry of the pelvic landmarks does not validate that the SIJ is the cause of that asymmetry. That belief has been negated and reinterpretation is timely.

Additionally, a study by Dr. Tycho Tullberg of Sweden suggests that there is no intra-articular reposi-



tioning with SIJ manipulation, which effectively discourages this treatment.⁸¹ However, the sample size was small (10), and more than 90 percent of the SIJ tests went from positive to negative after intervention, which is a very unusual occurrence, which I do not experience in the clinic.

The treatment method was atypical, utilizing four different techniques – again, not a usual clinical practice. Lastly, no mention of the type of SIJD was made, such as a sacral torsion, an anterior ilium, or pubic bone downslip, as though SIJD was a mechanically non-specific condition, which it is not. Obviously, cautious interpretation is advised.

Research by Gali Dar, an Israeli physical therapist and instructor at Tel Aviv University, discourages traditional mobilization in older age groups based on degenerative changes reducing motion.⁸² Using 3-D CT scans, it was revealed that six percent of males ages 20 to 39 and 47 percent of males ages 80 and above had fused SIJs. Interestingly, only three percent of females ages 22 to 93 were fused.

At times, radiographs create a false sense of objective validation of SIJD and SIJ disease.^d A very relevant and perhaps obscure fact is that none of these “objective radiological studies” measured the presence or absence of concomitant motion in the symphysis pubis, which, by design, always occurs with SIJ motion.

It is objectively established that a radiographic positional artifact is readily perceived with minimal axial rotation of the subject’s trunk and pelvis, such that the Gonstead Method of radiographic analysis easily renders false positives for so-called SIJD.⁸³ This is a chiropractic technique, which must be interpreted cautiously, and perhaps should not be utilized to diagnose SIJ motion dysfunction. The Gonstead study applies only to supine radiographs, though standing films plausibly suffer from the same drawbacks.

A separate study affirmed that the appearance of transverse plane rotation in radiographs does not accurately correlate with actual degrees of rotation in supine posture on the X-ray table.⁸⁴ A recent retrospective study indicates that radiographs in the prone position, in addition to conventional pelvic or lumbar spine views, did not provide any significant additional information in the majority of patients.⁸⁵ Asymmetry of left and right SIJ and

pelvic bony development is not uncommon, adding further caution to radiographic interpretation of purported SIJD.^{86,87}

Given the conflicting research, should the cautious clinician proceed and treat the SIJ region traditionally, or avoid the problem entirely? Neither answer provides satisfaction. A new paradigm needs to emerge to balance our perspective on the topic. First, we will review research that encourages SIJ treatment, to seek a balanced perspective on this controversy.

A very relevant and perhaps obscure fact is that none of these “objective radiological studies” measured the presence or absence of concomitant motion in the symphysis pubis, which, by design, always occurs with SIJ motion.

Some research encourages SIJ and lumbopelvic treatment

Some clinicians report beneficial responses to SIJ manipulation. Several studies demonstrate there is clinical utility in reducing muscular inhibition of the abdominals and quadriceps by treating the SIJ.^{88,89} Studies also suggest treatment of the SIJ for altering lumbopelvic recruitment⁴² and active straight leg raising neuromuscular strategies and respiratory function,⁹⁰ as well as for reducing urinary urgency, pelvic pain, and other genitourinary symptoms, including interstitial cystitis.⁹¹⁻⁹³

Physical therapist Michael T. Cibulka⁹⁴ has elucidated a relationship between impairments in the SIJ, hip, and subtalar joint restrictions, while physical therapist Rinus Voorn⁹⁵ has made the case that

^d Oftentimes, radiographs give the false impression of pathology or fusion of the SIJ, when contrasted with CT scans. Radiographs of the SIJ must be interpreted cautiously. Conventional pelvic CT can provide valuable information concerning the SIJ, and the CT appearance of the SIJ is closely related to the patient’s age, gender, and BMI.

a backward rotation fixation of the right ilium may have changed the kinematic chain of the lower extremity and caused a tendinitis in the Achilles tendon of the affected leg.

Perhaps some of the treatment techniques did not actually isolate the SIJ. Instead, they may have encompassed lumbar segments and retro-articular SIJ soft tissues. These structures, including muscles, tendons, ligaments, and the joint capsule, are richly innervated with mechanoreceptors that influence muscle function through a variety of feedback loops.^{96,97}

No doubt, manipulation – even if not specific to the SIJ – can influence these receptors in the lumbopelvic region. All manual therapists should be knowledgeable regarding these powerful influences on muscle tone, muscle strength, endurance, and pain. SIJ mobilization or manipulation can certainly have a clinical effect, but the treatment may have less specificity than purported, and it may affect the surrounding soft tissues, rather than reposition the joint. Additional research may shed more light on the subject.

Dr. Naotoshi Sakamoto and team suggest that the SIJ may be a source of low back pain, as the majority of mechanoreceptors (97 percent) are Type III nociceptors, the other three percent being proprioceptors.⁹⁸ Dr. Karolina M. Szadek and her fellow researchers performed a detailed histological study of the intra-articular and extra-articular SIJ nociceptors.⁹⁹ Researcher and orthopedic surgeon Dr. Eiichi Murakami performed a remarkably enlightening injections study effectively countering the belief that injection into the SIJ is a “gold standard” in terms of diagnosing the SIJ alone as the pain generator.¹⁰⁰

Murakami and colleagues performed intra-articular injections in 25 consecutive patients. The SIJ injection provided relief in only nine of the 25, or 36 percent. Among the following 25, who received peri-articular (primary ligaments and soft tissues) injection, 100 percent achieved pain relief. The

researchers concluded that when SIJD is a painful local condition, pain generation is not from the intrinsic portion of the joint in the majority, and terms such as *extra-articular* or *peri-articular SIJ pain* may be more cogent. Repeat studies are needed.

Given the significant overlap of the relevant lumbar and sacral dermatomes, sclerotomes, and sensory nerves encompassing L2-L3-L4-L5-S1-S2-S3, cautious interpretation is mandated. It should be mentioned that current thinking is to use a cluster of tests, such that a positive SIJ injection would require positive mechanical tests, congruent with the history and overall presentation, in order to diagnosis mechanical (as opposed to inflammatory) SIJD.

Injection can reduce overall pain along the *extrinsic* pathways of these nerve levels, reducing pain that is of primary lumbar segment origin. Therefore, the term “gold standard” is overstated when it comes to diagnosing the SIJ as the *primary* pain generator. It seems reasonable to also perform lumbar injection, and contrast those results with the SIJ injection.

Anatomically, the lumbar spine is connected to the sacrum via the last lumbar disc, the lumbosacral facet joints, and proximal soft tissues. The lower lumbar segments are connected to the ilia via the iliolumbar ligaments and other proximal soft tissues. The SIJ shares a similar connection with the bony pelvis and hip. This deepens the complexity of isolating the primary pain generator in structures that have a similar neural pathway.

This complexity is certainly humbling to those clinicians who accept the clinical reality, insightfully stated by osteopathic physician Dr. Alvin Stoddard, “The differential diagnosis between sacroiliac dysfunction and low back pain is difficult.”¹⁰¹

New Zealand physiotherapist, researcher, and professor Dr. Mark Laslett has described some diagnostic success with a small cluster of manual pain provocation tests, as they correlate well with positive SIJ injections.⁵³ Cautious interpretation is warranted

SIJ mobilization or manipulation can certainly have a clinical effect, but the treatment may have less specificity than purported, and it may affect the surrounding soft tissues, rather than reposition the joint.

because these tests also stress the lumbar spine and the hip, and because of the limitations of the “gold-standard” diagnostic injection, as stated above.

The ability to specifically isolate the majority of the force application to the SIJ and not the hip or lumbar spine has yet to be thoroughly researched. It seems as though these studies and their impact on the profession provide a sense of permission-granting to treat the SIJ with manual procedures. However, many more clients have faulty posture and faulty motion coupling in the lumbopelvic-hip region, such that a biomechanical model, rather than a pain-provocation model alone, may be more appropriate for this population. I submit that both models have relevance in differing populations. Hands-on clinicians may be frustrated with limited the ability to confidently reproduce or rule out SIJ pain.

A biomechanical perspective encourages treatment to enhance posture and mobility of the pelvis, hip, SIJ, and proximal structures. Reduction in pain may be facilitated by enhancing function through the restoration of optimal posture, movement, muscle tone and length, and so on. This encapsulates my philosophy regarding movement testing versus pain provocation with manual tests. In support of movement testing, next we will discuss a fluoroscopy study.

This very unique and enlightening SIJ movement study was presented by the orthopedist Dr. Thomas N. Bernard, who demonstrated SIJ motion with a small cluster of pain provocation, gross/macro-motion, and spring/micro-motion tests applied to the sacrum and the ilia with real-time fluoroscopy.¹⁰² Perhaps appearing paradoxical, the fluoroscopy video seemed to clearly convey that motion transfers *through* the SIJ, and it is functionally relevant and of normative anatomy, physiology, and biomechanics.

This finding is much more relevant than the concept that motion occurs only *within* the SIJ. It is rather striking to note that all the motion induced via traditional tests and via spring/micro-motion tests provoked a similar response in the joint – compression and recoil. This is quite different from the anticipated rotation and glide, and it seems fitting for a joint that has a primary function as a shock absorber and three-dimensional force transducer.

The fluoroscopy video seemed to clearly convey that motion transfers through the SIJ, and it is functionally relevant and of normative anatomy, physiology, and biomechanics.

Perhaps the joint does, in fact, function with compression and recoil throughout much of the articular surfaces during normal motions of the body, whereas end-range positions with large passive forces – such as superincumbent body weight and especially external ones – are required to induce true joint fixation.

The insight of physical therapist and professor Joan M. Walker, stated here, resonates with my belief: “The minimal range of motion present in probably most of the population casts doubt on whether therapists can detect 1 to 3 degrees or 1 to 3 millimeters of motion occurring specifically at the SIJ. Perhaps the term ‘play’ should be used when referring to the SIJ, as ‘motion’ connotes the idea of a quantity of motion similar to other synovial joints, which does not appear to be the case.”¹⁰³

Re-interpretation of the SIJ paradigm, as opposed to overall dismissal, seems prudent. This fluoroscopy study significantly altered my paradigm to one of acknowledging that structures *extrinsic* to the SIJ could reduce physiological motion that ideally moves *through* the SIJ.

SIJD is More Common in Females

There is one aspect of SIJD that the majority of clinicians agree upon, including even the most strident deniers of the general SIJD paradigm. The vast majority acknowledge that SIJD in the female is a valid paradigm due to gender-specific anatomy and physiology, including hormonal influences, pregnancy, and birth mechanics, which, of course, can be enhanced by passive trauma or repetitive strain in the adult female. Therefore, clinicians should become very skilled in treating this population. To do otherwise would be an archaic form of gender-specific insensitivity and prejudice.

Studies through several decades have addressed the problems of pain, vulnerability, and hypermobility of the sacroiliac joint and symphysis pubis during the menstrual cycle, as well as during and after pregnancy. Contributing factors include increased levels of the hormones relaxin and estrogen, the growing fetus, and the birthing mechanics.^{91, 104-124}

In life, female pelvises are more mobile than male pelvises,^{125,126} perhaps making them more vulnerable to having late-life SIJD. Early postpartum females have significantly larger distances of the inter-pubic gap, with significantly different radiographic signal density, indicating much greater water content in the cartilage.¹²⁷

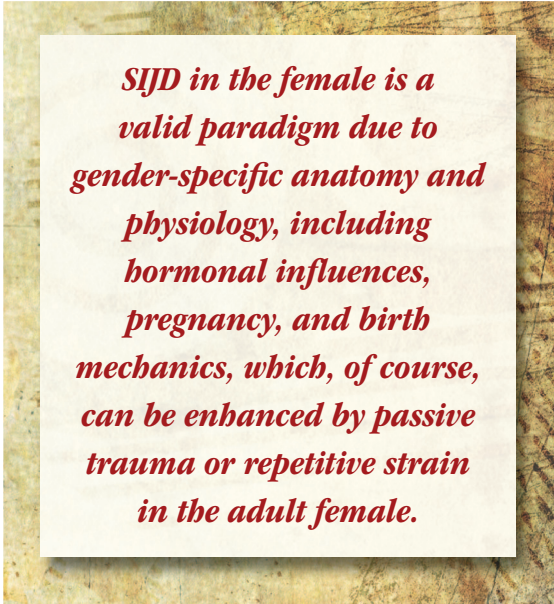
The role of hormonal influence and pregnancy on SIJD is worthy of continued exploration. While hypermobility is frequently cited in the literature and by clinicians treating this population, hypomobility and treatable joint fixation are also highly relevant, yet under-appreciated. These issues are addressed in an interesting case study, which follows shortly.

Paradoxically, sometimes a clinician erroneously assumes that pain is caused by a late pregnancy pelvic joint instability, when the problem is actually a true SIJ fixation. In spite of the SIJ and symphysis pubis fixation, the client can still feel as if she is coming apart in the symphysis pubis and SIJ. How is this paradox possible? Nociception from visceral structures, such as the uterus and bladder, can provoke the subjective sensation of pelvic joint instability. For example, pressure on the bladder, compounded by posture and the expanding uterus, stimulates the organs' stretch receptors/nociceptors. The visceral pain generators may easily facilitate referred pain, as the viscera and joints may have a shared proximal nerve supply.

In a recent case study, I treated severe, late pregnancy pelvic pain, subjectively described by the client as "severe instability," in a one-hour session with immediate and lasting benefit.⁹² The hands on-on screen indicated a lack of SIJ and symphysis

pubis mobility. Treatment consisted of restoring anterior glide mobility of the sacrum and postero-medial mobility of the ilia, and then reducing a bilateral anterior pelvic tilt. Low load and long duration force application was used to optimize comfort during treatment and encourage viscoelastic creep^e deformation of the connective tissues.

This treatment type is a fundamental concept of the Hesch Method. The client moved in a very protective manner, using a narrow base of support, and she kept her knees together when performing positional changes, such as rolling to the side, sit to stand, and so on. She certainly *appeared* to have pelvic instabil-



SIJD in the female is a valid paradigm due to gender-specific anatomy and physiology, including hormonal influences, pregnancy, and birth mechanics, which, of course, can be enhanced by passive trauma or repetitive strain in the adult female.

^eViscoelastic creep is a fundamental property of connective tissue, and it is relevant as a treatment technique. A constant load applied will cause initial elongation or deformation of the tissue, as this engages the elastic component. Releasing the force allows a return to normal length. A prolonged, constant force will take the structure beyond the elastic limit and start to induce a lasting length change. Elasticity describes the property that allows a return to original length. Viscous refers to flow or deformation. Creep is deformation over time. This concept is well understood by myofascial therapists, and I hope that, in time, it will become the new standard of practice for joint mobilization/manipulation. At present, by definition, joint manipulation implies a low-to-moderate amplitude, high-velocity thrust, and reformatting the definition would have to be part of the viscoelastic creep paradigm change.

ity, yet she actually had pelvic joint hypomobility with joint fixation. This case study is iconoclastic, and contrary to the literature, challenging the prevailing paradigm of pregnancy-induced, symptomatic pelvic joint hypermobility.

In this client, the benefit of a single intervention to restore lost mobility in the pelvic joints went beyond simply reducing acute pain, the sensation of instability, and antalgia. Treatment also significantly improved bladder control and reduced long-term pain diagnosed as *interstitial cystitis*. Benefits lasted more than nine months, at which time she returned for a single intervention for low back pain.

The treatment that restored joint mobility also improved her pelvic posture, showing that one cannot isolate the joint mobilization to a single effect, as SIJ motion restoration also improved pelvic posture. It seems reasonable that posterior sacral glide fixation may have caused excessive tension on the lower sacral nerves. The lower sacral nerves do contribute to the nerve supply of the pelvic floor and lower pelvic viscera.

The sacrotuberous and sacrospinous ligaments were hypertonic, and this may have affected tension and compression along the proximal pathway of the pudendal nerve. One can reasonably argue that pelvic hypermobility was a pre-existing condition, which allowed the joint to move into a stuck position. This would be congruent with the client's soft tissue type.

Alternately, the SIJ and pelvic restriction may have preceded the pregnancy. Regardless of validity, the successful intervention was antithetical to traditional care – which addresses purported pelvic joint instability – and most likely facilitated the relative “ease of delivery.” In this example, a functional activity screening would *not* have been as informative as hands-on passive joint movement testing, typically referred to as spring/micro-motion testing. This method of spring/micro-motion movement testing will be addressed in detail later on.

SIJD misdiagnoses in a female

SIJD is not only *difficult* to diagnose, it is also, unfortunately, easy to *misdiagnose* as well. Such misdiagnoses can lead to protracted, costly, and ineffective treatment. Regardless of the best of intention, some traditional and alternative or complementary health practitioners sometimes tend to *medicalize* SIJD diagnoses, when, oftentimes, rational, early intervention can provide significant and lasting benefit.

The term *medicalize* refers to the process of giving a greater significance to a simple condition, and assigning a protracted time frame – a chronicity – to the condition.

For example, in a healthy person, a bruise is a short-lived phenomenon, whereas chronic diabetes

is a lasting medical condition. The bruise does not need protracted care, but diabetes does. Most cases of SIJD should swiftly resolve if appropriate care is provided early on.

I recently treated a client who – despite three imaging studies to the contrary – had been misdiagnosed with instability of the SIJ and symphysis pubis instability. On her initial visit to me, she presented with a simple case of treatable bony pelvic asymmetry. The client is now self-managing the SIJ/pelvic asymmetry, and it may well be resolved. It did not behave like an unstable SIJ. She required only one visit to address it with manual therapy, and she was then taught self-management.

In contrast to this approach, she had received care that had exceeded \$15,000 dollars in out-of-pocket expenses, with no apparent end in sight – all this for purported “SIJ instability.” She also had lower abdominal neuropathies that, unknown to her previous care provider, contraindicated the type of care she was receiving. This client had severe lumbar pathology as well, validated by pain provocation tests, including

***Health practitioners
sometimes tend to medicalize
SIJD diagnoses, when,
oftentimes, rational, early
intervention can provide
significant and
lasting benefit.***

lumbar spring tests, which were congruent with the imaging studies.

She and her husband had received conflicting information for a protracted period of time, and the SIJ was given too much credibility. This case study is a perfect example of the problems that arise when the wrong diagnosis is *medicalized*, as well as the types of problems we face with SIJD diagnoses. As research adds to the knowledge base, patient care will continue to improve. Hopefully, a team approach will also help foster optimal care.

Other causes for SIJ instability

In addition to hormones and pregnancy, there are other causes of hypermobility. True SIJ instability is clearly established as related to lumbar fusion.^{55, 128-132} Traumatic instability is also present in the pediatric population.¹³³

Now that we have explored some causes for bona fide SIJD and a misdiagnosis, we can leave the theoretical and move onto the practical, starting with the palpatory evaluation of the sacru



Torsion Evaluation

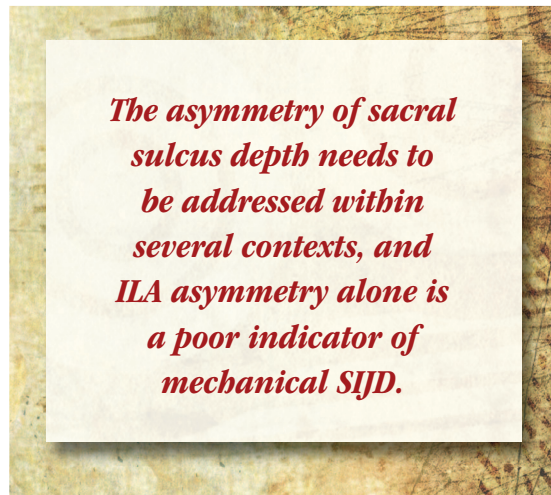Sacral palpation

The screen for torsions involves a few sacral palpation tests, which are used to determine anterior to posterior (A-P) symmetry on the dorsal surface of the sacrum. This includes the sacral base, the sacral sulci, and the dorsal surface of the inferolateral angles (ILAs). The undersides of the ILAs are also screened to assess symmetry, or the presence of a side-bending fixation.

Palpation of the sacral sulci can be problematic, as a change in the sacral sulci does not necessarily describe a positional change of the sacrum. It only gives information about the *relationship* of the PSISs and the sacrum, with a considerable amount of deformable soft tissue in between. One could have an altered ilium and a normal sacrum, again with an altered sulcus. Increased muscle and tendon mass, such as unilateral hypertonicity of the multifidi, along with erector spinae muscles and tendons overlying the sacrum, can cause a false positive palpation test.^{28,134}

Research has shown that electrical stimulation of the dorsal SI joint capsule does provoke the greatest response in the multifidi, while ventral stimulation facilitates the gluteus maximus and quadratus lumborum.⁹⁶ These receptors also respond to inflammation

and mechanical deformation. In response to injury, these receptors and muscles can cause observable and palpable lumbopelvic-hip asymmetry, in the absence of glide or rotation in the SIJ. In conclusion, the asymmetry of sacral sulcus depth needs to be addressed within several contexts, and ILA asymmetry alone is a poor indicator of mechanical SIJD.



The asymmetry of sacral sulcus depth needs to be addressed within several contexts, and ILA asymmetry alone is a poor indicator of mechanical SIJD.

The ILA screen is used to determine anterior/posterior and superior/inferior position of the sacrum, which presents a unique challenge. Due to developmental asymmetry, the uneven ILAs can give a false positive, so additional sacral landmarks need to be used to reduce error, after which movement tests must be performed.

Altered soft tissue tone of the sacrotuberous and sacrospinous ligaments can be a direct result of altered muscle tone. Pelvic postural asymmetry will alter muscle tone. Several muscles originate or insert on the sacrum, and partially on the sacrotuberous and sacrospinous ligaments. These ligaments can be hypo- or hypertonic in direct response to altered muscle tone, such as the pelvic floor, hip rotators and extensors and even the long head of the biceps femoris.

At times, the long head of the biceps femoris partially or fully bypasses the typical insertion onto the ischial tuberosity, and instead inserts directly onto the sacrotuberous ligament. A study by Dr. Andry Vleeming and his colleagues showed that SIJ mobility can be reduced in end-range positions that tense these muscles.¹³⁵

Spring/micro-motion testing can overcome the aforementioned barriers in discerning whether the client's presentation is a true articular *motion* restriction, though it cannot (nor can any clinical test) discern if it is an intra- or extra-articular cause. Nonetheless, the information is much more vital, and restrictions missed with the traditional SI gross/macro-motion tests can be discerned. Worth repeating is the relevant concept that we are screening for treatable motion that is blocked, not allowing forces to travel through the SIJ, as opposed to the illusion that we can discern motion loss in the SIJ. The client is better served when the practitioner grasps this concept.

The term "gross/macro-motion tests" refers to the typical tests used to implicate the SIJ as the source of pelvic asymmetry. In my opinion these tests are the *least reliable criterion* for a true sacroiliac joint dysfunction.¹³⁶ Examples include the standing hip flexion test, the long sit, the standing and sitting spine flexion, and the prone knee flexion test. In addition, these tests do not, individually, have a high inter-tester reliability.¹³⁷

A long-standing clinical belief is that the sitting SIJ palpation and motion evaluation reveals more about sacral movement dysfunction, whereas the standing examination reveals more about movement dysfunction of the ilium/ilia. This belief is theoretical at best. Upon reflection, it seems reasonable to discern that if there is asymmetry of the pelvis prior to sitting, the sacrum and ilia will both be asymmetrical in the static and dynamic seated contexts.

***We are screening
for treatable motion that
is blocked, not
allowing forces to travel
through the SIJ, as
opposed to the illusion
that we can discern
motion loss in the SIJ.***

While sitting, I can readily move either ilium in any direction, and asymmetry would alter resting trunk position. Thus, motion induced from above down through the sacrum would surely be altered, not because of the sacrum, but because of the ilium. We simply cannot easily discern whether the ilium or the sacrum is the primary restriction using the above tests.

Spring/micro-motion tests can overcome these evaluative barriers, discerning which structure has blocked motion, and in which direction. Prior to learning the spring/micro-motion tests, it is helpful to be able to visualize the appropriate axis of motion in each cardinal plane of the body.

Visualizing the Oblique Axes and Motion

Transverse and frontal plane views of oblique axes. The axes have a slight anterior and posterior orientation when viewed in the transverse plane from above (Fig. 6) and when viewed in the sagittal plane (Fig. 7). This anterior-posterior portion of the axis^f accounts for side-bending, and treatment that corrects the primary rotation automatically corrects the side-bending component. Undergirding this claim are decades of performing evaluations using modified passive spring/micro-motion tests (Springing with AwarenessSM, defined later in this chapter) and testing for residual side-bending restriction after correcting the primary rotation.

There are only two oblique sacral axes (Fig. 1). The axes are named for the top portion of the axis. Therefore, the *left* oblique axis originates above the *left* upper quadrant of the sacrum, and it terminates lateral to the right inferior sacral quadrant. The *right* axis is a mirror image, originating above the *right* upper quadrant of the sacrum, and it terminates lateral to the left inferior sacral quadrant.

When the sacrum is torsioned, *only one* sacral quadrant will be prominent and stuck, per sacral palpation and posterior-anterior quadrant spring/micro-motion-testing. The quality of being stuck is not subtle and can be discerned with spring/micro-motion testing, which is a valuable clinical tool.

The primary motion in torsion is rotation, and the most prominent sacral quadrant indicates the direction of rotation fixation, either right or left. For example, left rotation on left upper oblique axis indicates *left* rotation fixation of the prominent left lower sacral quadrant, in which the front of the sacrum faces to the left (Fig. 8).

Perhaps not necessarily intuitive, it is worth noting that the sacrum will be symmetrical at S2 where either axis crosses the midline (Fig. 9). The left and right oblique axes cross the midline at S2, and

only at this location are the palpatory landmarks equidistant to the axis. Now that you can visualize the oblique axes, you are prepared to appreciate the relationship between the palpation and the spring/micro-motion tests for torsion screening.



Figure 6: This image shows the **top view of the sacrum with left oblique axis**. Viewing the sacrum from above, the slight anterior orientation of the upper part of the left oblique axis is readily discerned.

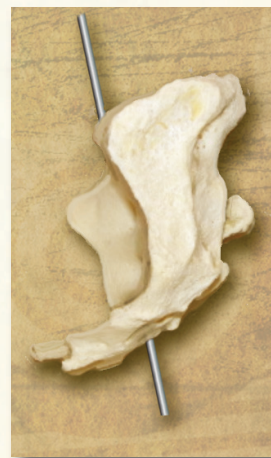

Figure 7: This image shows the **sagittal view of the sacrum with left oblique axis**. Viewing the sacrum from the side, note the slight anterior orientation of the upper portion of the left oblique axis.

^f The oblique orientation of the axis in the dorsal plane contributes to the side-bending sacral motion. Contrast this with a purely vertical axis, in which pure rotation occurs without any side-bending. Note that the oblique axes have a slight A-P orientation, which is visualized in both the transverse plane and in the sagittal plane. This is the portion of the axis that accounts for side-bending.

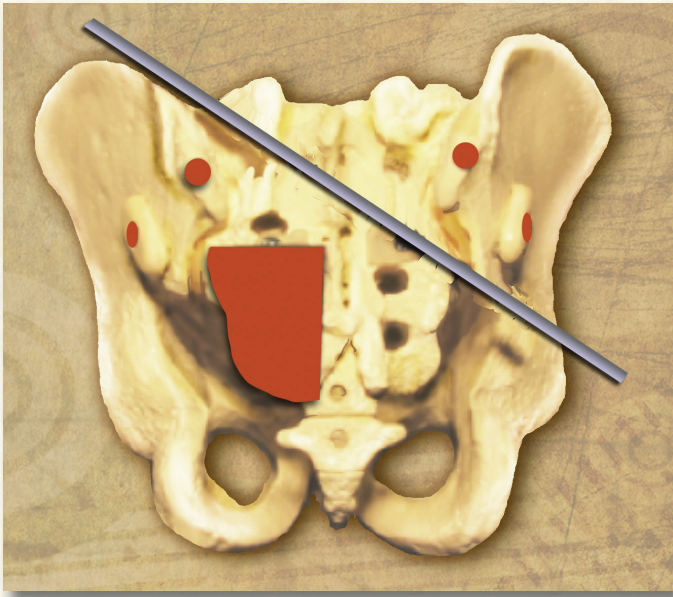


Figure 8: With torsion, one sacral quadrant will be prominent. In the presence of a sacral torsion the sacrum will be most asymmetrical at only one side of the sacral base or apex. In the most common torsion, the left lower sacral quadrant is prominent.

Figure 9: The sacrum is symmetrical in the midline with torsion. With torsion, the sacrum will only be symmetrical at S2 to the left and right of midline.

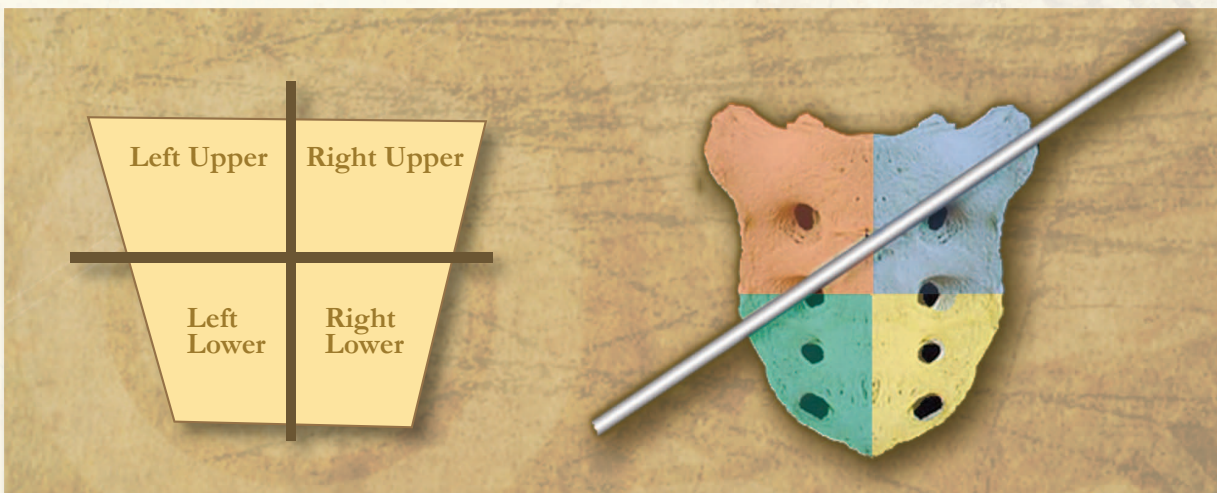
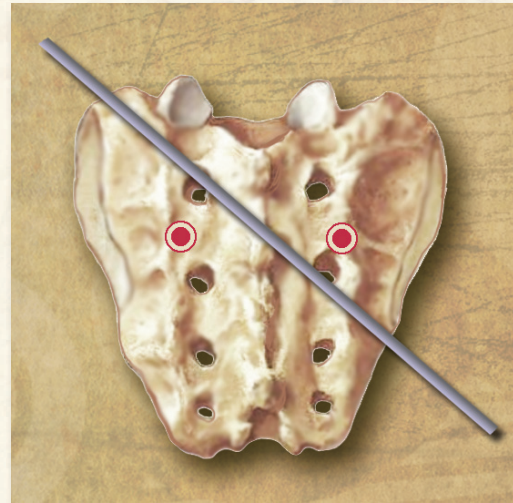


Figure 10: This shows the four quadrants of the sacrum. Four sacral quadrants are created by visualizing or drawing a vertical line down the middle of the sacrum and drawing a horizontal line at the middle of the second sacral segment, which lies between the PSISs.

Sacral Palpation

Traditional palpation of the sacrum to establish A-P position is performed bilaterally at the sacral sulci located at S2, where the thumbs drop medially off the PSISs – the sacral base at S1, and the dorsal face of the ILAs at S5. The ILAs are also bilaterally palpated on the inferior border to discern superior-inferior position. The Hesch Method¹³⁸ adds bilateral palpation of S3 and S4 sacral segments, so that all sacral bony segments are palpated for completeness. This method can reduce error and distinguish torsion from a pure rotation about a vertical axis.

In his text *Principles of Manual Medicine*, Greenman¹³⁹ insightfully advocates screening the tone of the sacrotuberous and sacrospinous ligaments as part of a thorough SIJ screen.⁸ I agree that this is very relevant for torsions. The sacrotuberous ligament will typically present as hypertonic on the side of sacral rotation, due to tri-plane repositioning of the lower sacrum, whereas the contralateral sacrospinous ligament will be slack.

For ease of screening the rotational component, this approach names four sacral quadrants: upper left, lower left, upper right, and lower right sacral (Fig. 10). These quadrants help demonstrate the location for the passive motion tests. When you spring above and below the left oblique axis, note that the right upper and the left lower quadrants are screened. Springing above and below the right oblique axis addresses the left upper and right lower quadrants.

When learning to evaluate and treat torsions, it is helpful to draw a left oblique axis with a non-toxic marker, or place a pen across the sacrum of your volunteer (Fig. 11). Later, you can create the right oblique axis by repeating the above on the opposite side (Fig. 12).

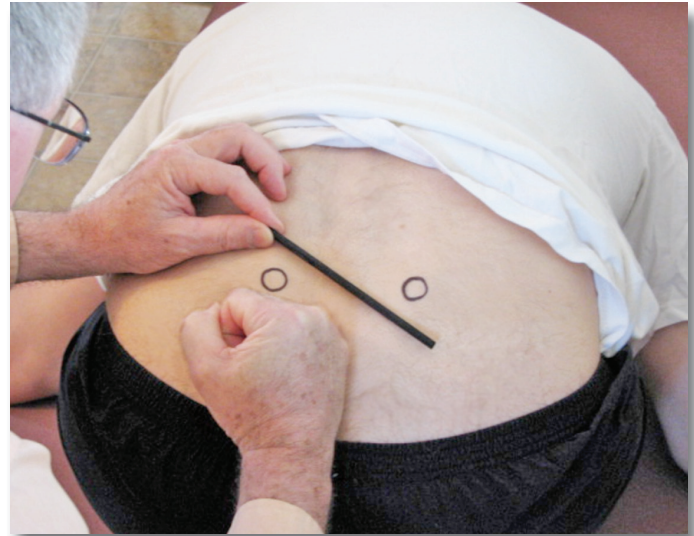


Figure 11: A pen represents the left oblique axis on the client's sacrum. The left oblique axis is named for the top of the axis, which originates on the left side. The left oblique axis separates the sacrum into an upper right and a lower left half.

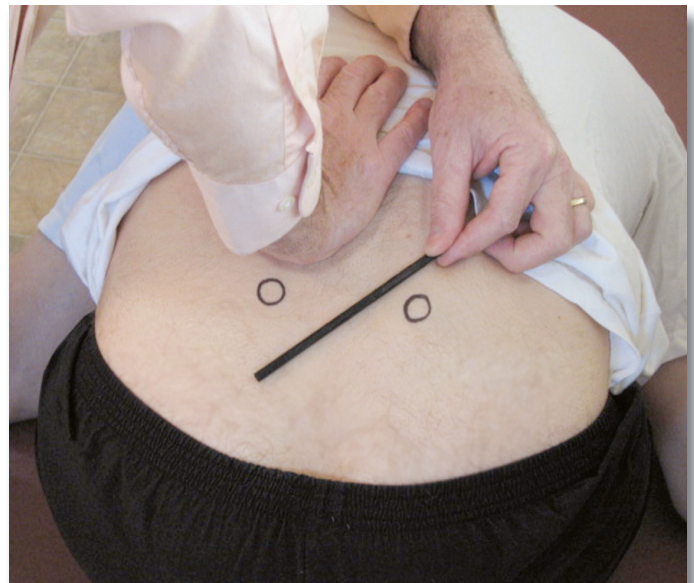


Figure 12: A pen represents the right oblique axis on a client's sacrum. The right oblique axis is named for the top of the axis, which originates on the right side. The right oblique axis separates the sacrum into an upper left and a lower right half.

g Palpation of the long dorsal ligament and sacrospinous ligament is also encouraged, though for the purpose of our discussion on torsions, the sacrotuberous is particularly relevant. I perceive an aversion to ligament palpation in some clinicians, which I fail to understand. It has been remarkably informative for me.

Sacral Spring Motion Testing

Springing with AwarenessSM theory

The traditional sacral evaluation is thorough and does include passive sacral motion testing, described as both springing and sacral rocking.¹⁴⁰ Traditional spring is a forward thrust, done at each ILA in a P-A direction, in which the clinician uses short and quick pushes to evaluate the yield or play. Rocking is performed with downward pressure with alternate thumbs above and below one oblique axis at S1 and S5.

I find the traditional sacral evaluation difficult to use, as it only gives me half the movement information – the forward portion. Joints have a normal elastic recoil, which cannot be perceived with thrust-forward spring tests. Hesch springing differs in that it allows the important perception of this recoil. I have been developing Hesch springing for three decades, and applying it to the ilium, ischium, sacrum, symphysis pubis, and so on. I developed additional tests and treatments when I encountered movement dysfunctions not described in the literature.

For at least four decades, physical therapists trained in orthopedic manual therapy evaluated passive accessory motion in nearly all joints in the body, yet did so minimally at the SIJ and pelvis. Extensive spring/micro-motion testing of the SIJ and pelvis continues to be absent in contemporary manual therapy writings.¹⁴¹

Hesch springing¹³⁸ is also referred to as Double Recoil Spring Testing. I gratefully acknowledge Rob Shapiro, M.A., P.T., C.O.M.T., for naming my spring technique “Springing with AwarenessSM.” This method of mobility testing can be applied to many joints and structures in the body.

It can also be applied to the sacrotuberous, the sacrospinous, and the long dorsal SIJ ligaments. These ligaments will have altered tone in response to SIJD, particularly in response to torsion. The ligament tone is dynamic, and both hypotonic and hypertonic ligaments are often quickly restored to normal with manual therapy techniques.

I find the traditional sacral evaluation difficult to use, as it only gives me half the movement information – the forward portion.

The fact that muscle length has a significant influence on ligament tone in several regions of the body, including the pelvis, is a very underappreciated clinical fact, but a deep inquiry into the fascial expansions nearly makes muscle and ligament one and the same. Changing ligament tone changes the mechanoreceptors, which have feedback loops with muscle. The big reach, then, is the concept that reflex activity can not only

influence muscle tone, but also ligament tone. Not detailed here, I do have an approach to ligament laxity that involves the reduction of mechanoreceptor inhibition on muscle tone, applied only to grades I and II laxities.

Traditional forward-thrust spring tests are performed by pressing against a bony structure with moderate force until a resistance is perceived, in order to *take up the slack*, primarily in the elastic component of surrounding soft tissues. In other words, the potential movement is taken out of the surrounding soft tissues, so movement will be created within the joint if additional force is applied. This joint movement is graded qualitatively and, under research conditions, quantitatively.

Whether a forward-thrust or an advanced spring/micro-motion test is used, it is appropriate to suggest that motion *primarily* occurs in the joint. With large structures such as the pelvis and pelvic bones, it seems reasonable to presume that slight motion may occur in the surrounding joints and/or soft tissues, in spite of our best effort to isolate forces.

Our hands-on joint stabilization with large structures such as the pelvis and SIJ may have inherent limits in real-world clinical practice, as opposed to near perfect three-dimensional stabilization in a research laboratory. This may change our focus from normalizing motion and stability in the SIJ to optimizing movement and stability in the functionally integrated system named the “lumbopelvic-hip complex.”

Those who perceive SIJ mobilization as *irrelevant* because of the small motions that normally occur may see value in treating the system, acknowledging that *extrinsic* restrictions can reduce motion occurring *through* the SIJ and pelvis. Women's back pain of pelvic and SIJ origin is then acknowledged, evaluated, and treated with the same vigor and commitment as other types of back pain.

Traditional spring tests can give false positive results when done with haste and imprecision. Hesch springing slows down the process and helps reduce errors. Why is this so? Rather than letting go of the force after the forward spring, the clinician can, instead, allow the structure to recoil back to the loaded position, where the slack was taken up. The clinician can repeat the forward spring and perceive the recoil several times without having to take up the slack each time.

This subtle change allows greater focus on relative quantity and quality of motion. The skill of Springing with AwarenessSM can become second nature with a little bit of practice. I could never go back to the traditional forward-thrust spring test only. I would feel like half the information was missing (the recoil). Especially with regards to instability, it is the slow reduced elasticity of the recoil that is informative.

A normal joint will have a specific spring-like feel throughout the spring/micro-motion test. The clinician will be able to take up the slack similar to compressing a spring and will then be able to impart the forward spring and perceive the spring-like recoil, if joint motion is normal. There is a distinct *spring-like* feel to the recoil of the sacrum, and at any other joint with normal motion. It seems appropriate that the newer method is named "Springing with AwarenessSM," whereas the traditional method would be more accurately named a "forward-thrust test."

In contrast to the normally springing joint, an extreme abnormality would be blocked motion, in which minimal or no slack is available, after which the joint cannot spring forward. Typically, these presentations are treatable conditions, with a few exceptions that will not be addressed here.

Another possible abnormality is the perception of

abrupt recoil, which indicates reduction in normal mobility, although the joint is not stuck. In contrast, much slower recoil of the joint indicates hypermobility. The technique for performing this test with a specific amount of force will be detailed in the next section.

Spring/micro-motion tests are research-based. The research shows that clinicians can readily learn to apply specific forces with good short- and long-term reproducibility.¹⁴²

It is important to recognize that blocked motion in the SIJ can have an *extrinsic* etiology, and so Hesch springing does not measure motion that is only blocked *within the SIJ*. The springing discerns that motion cannot occur *through* the SIJ. Extrinsic motion

restrictions are probably much more common than actual intrinsic SIJ motion restrictions, and a combination of intrinsic and extrinsic motion block may also occur.

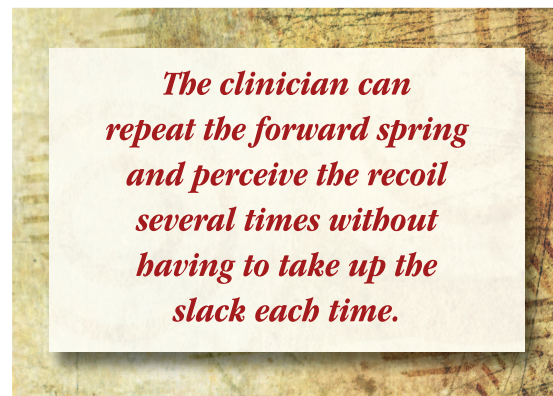
Earlier in this chapter, I spoke of the possibility that spring/micro-motion tests might not isolate *only* the intended joint. If we accept this possibility, we can easily accept that sometimes the joint is restricted from an extrinsic

structure, discerned with spring/micro-motion tests in a way that no other test can discern. This possibility encourages treatment of SIJD for those clinicians who deny that we can actually interpret the minute SIJ motions.

There is a leverage effect because passive tests are performed at a distance to the joint, such that motion is then amplified, not subtle. This perspective encourages more treatment directed to lumbopelvic motion dysfunction and bypasses a theoretical barrier to manual therapy of this region. Therefore, I submit that there is no valid argument against treating the "SIJ."

As stated previously, osteopathic theory does teach forward thrust (spring) and rocking of the sacrum,¹⁴³ though this is not addressed in the summary table on sacral dysfunction findings.¹⁴⁴ This oversight supports my contention that even the traditional forward-thrust spring tests seem to be generally de-emphasized, or presented as optional, in most writings and continuing education courses on SIJD.

To the best of my knowledge, *extensive* spring/



micro-motion testing of the other pelvic bony landmarks is not taught today in most works on SIJ treatment, with the exception of the works of physical therapist and professor Richard E. Nyberg,¹⁴⁵ as well as my own works, which include more than 27 distinct tests.¹³⁸ I do hope that this will change, as I believe it will only help patient care.

Next, we will cover the postures that are relevant when examining a patient for torsions.

Spring test posture

Spring/micro-motion tests cannot readily be performed in standing and seated positions due to body sway. At the segmental level, the axial joints can experience a large increase in momentary stability, as they are vertically compressed in upright postures. Also, there is facilitation of the anti-gravity physiological extensors, which increases joint compression as well, rendering spring/micro-motion testing difficult and, eventually, irrelevant.

These barriers are significantly reduced by positioning the client in the following positions: prone neutral, prone passive hyperextension, supine, yoga child pose, and side-lying. These stable positions reduce anti-gravity muscle tension, allowing a true and accurate spring/micro-motion test to be performed with more accurate palpation. Torsions that are present in prone neutral posture will always amplify in fully flexed postures, such as yoga child pose.

For me, treatment in the position of maximum dysfunction is a fundamental principle of care. Spring/micro-motion testing in non-weight-bearing postures may demonstrate that a joint is not actually stuck. Many appearances of torsion in prone or standing extension may then disappear, as they are most likely due to asymmetrical muscle facilitation.

Performing Hesch springing

In spite of any appearance to the contrary, Springing with AwarenessSM is a simple, straightforward tool available to clinicians who routinely evaluate soft tissues. This method of spring/micro-motion testing is simply an enhancement of the skill set of soft tissue evaluation, so that it can be performed on denser connective tissue.

Spring/micro-motion testing is a challenging read, and the readers are encouraged to first observe video on the topic to appreciate the simplicity and the sequential manner in which it is performed. Viewing the videos should make the reading much easier, by providing a dynamic visual frame of reference.

Searching YouTube.com using the key words “Jerry Hesch,” then “sacroiliac spring test” will lead you to several video demonstrations that contrast Springing with AwarenessSM with the traditional forward-thrust method. One video address false-negative and false-positive tests. These concepts

are quite relevant, especially if the concept of springing is novel to the reader.

For the rest of this chapter, any use of the terms *spring*, *spring/micro-motion*, *springing*, or *Springing with AwarenessSM* refers to the Hesch Springing with AwarenessSM technique, unless stated otherwise.

When preparing to do a spring test, be sure to orient the direction of force to the anatomical plane that is altered by the patient’s position, so that the direction of force is, indeed, a pure P-A directed spring/micro-motion test that is perpendicular to the posterior face of the sacrum. Initially, this method can seem challenging, but it can be easily learned with a little practice, while slowly reading the sequence with your hands on an anatomical model or volunteer. With practice, each spring/micro-motion test can be performed with three repetitions in 10 seconds or less.

These stable positions reduce anti-gravity muscle tension, allowing a true and accurate spring/micro-motion test to be performed with more accurate palpation.

Below, the procedure is abbreviated one line at a time.

Springing on a normal mobile sacrum

Palpate the sacral quadrants in yoga child pose (Fig. 13).

Step 1: Position hand to perform spring/micro-motion test with zero pounds on one quadrant (Fig. 14).

Step 2: Take up the slack using 10 pounds.

Step 3: Impart spring/micro-motion with an additional 10 pounds. The total force on the sacrum is now 20 pounds.

Allow the recoil to return to Position 2, maintaining the 10-pound position.

Repeat spring/micro-motion tests as desired, going from Position 2 to 3 and back to 2 as necessary.

Step 4: When finished springing, briefly hold the final 10 pounds and then let go to zero pounds.

Step 5: Repeat the entire test at the other three sacral quadrants.

Springing a sacral torsion

The above method of springing will work on sacral quadrants and joints that have normal mobility. The sacrum will behave differently when torsion is present. If torsion is present, you will be able to spring three sacral quadrants. However, you will not be able to take up the slack on the prominent and stuck sacral quadrant in yoga child pose, nor in prone neutral a small percentage of the time.

Even by increasing the force to 20 pounds or somewhat greater, the joint will not spring. In time, you will easily realize that the prominent sacral quadrant is always the stuck one, and you can skip the spring/micro-motion test and directly proceed to treatment.



Figure 13: The client is in the **yoga child pose position for torsion screening and treatment**. This is a stable position, in which the entire axial body is in full flexion. Torsions become most prominent in this position, making them easier to visualize, palpate, and spring/micro-motion test.

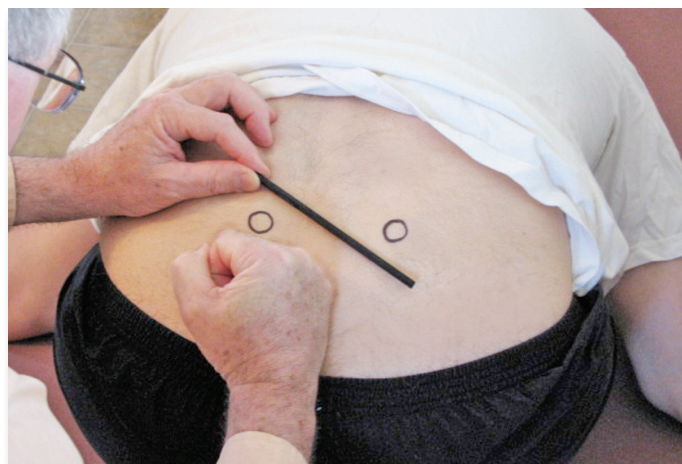

Figure 14: This photo shows a **spring test to left lower sacral quadrant below left oblique axis**. The circles overlies the left and right PSIS. The client is in yoga child pose position. The spring/micro-motion test is applied to the left lower quadrant, below the left oblique axis.

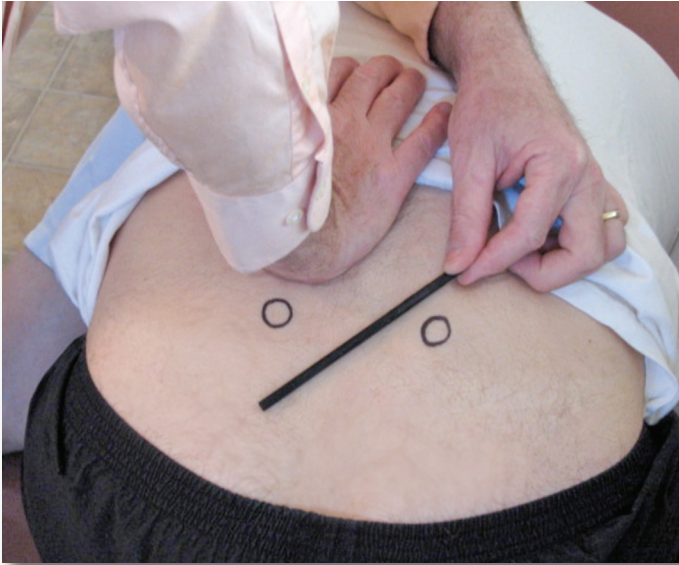


Figure 15: This photo shows a **spring test to the left upper quadrant, above the right oblique axis.** The circles overlies the left and right PSIS. The client is in yoga child pose position. The spring/micro-motion test is applied to the left upper quadrant above the right oblique axis.

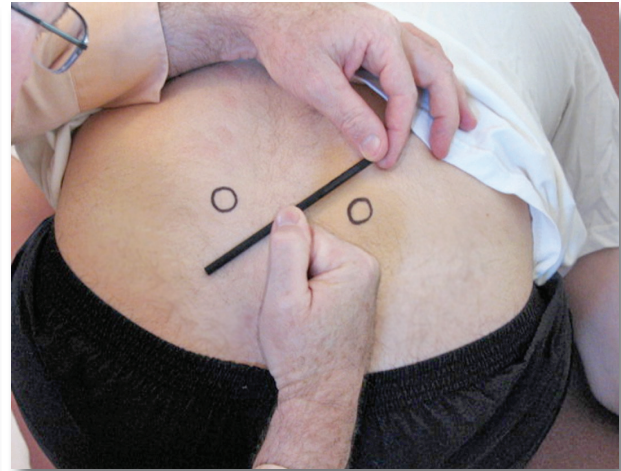


Figure 17: This photo shows a **spring test to right lower sacral quadrant, below the right oblique axis.** The circles overlies the left and right PSIS. The client is in yoga child pose position. The spring/micro-motion test is applied to the right lower quadrant, below the right oblique axis.

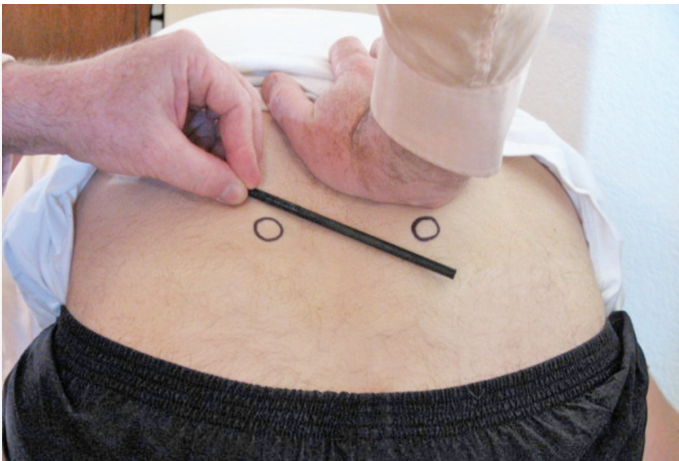


Figure 16: This photo shows a **spring test to right upper sacral quadrant, above left oblique axis.** The circles overlies the left and right PSIS. The client is in yoga child pose position. The spring/micro-motion test is applied to the right upper quadrant.

There are some videos on the topic, which you can find by searching for "Jerry Hesch," and then "sacral torsion" on YouTube.com. I believe the videos will be very helpful.

Treatment

The treatment position of client and clinician is the same as the position shown for springing. Only one treatment picture will be included, for the most frequently encountered torsion, which is left rotation about the left upper oblique axis. Treatment is simply a spring/micro-motion pressure that is maintained for two minutes, as described below.

Please note that when mobility is blocked, you will not be able to take up the slack, or if you can, it will be minimal, at which point no further motion is available. It may appear that only the superficial soft tissues will deform and not the joint. You will be able to take up the slack in the remaining three quadrants.

Sometimes, initial screening in prone neutral position may allow some slack to be taken up, which is then absent when the client gets into yoga child pose position. Other times, both positions reveal blocked mobility. Treatment will consist of applying approximately 20 pounds of force, maintained for two minutes. The sacrum will typically release within that time frame, and repeat testing should indicate normal mobility. A treatment disclaimer is provided.^h

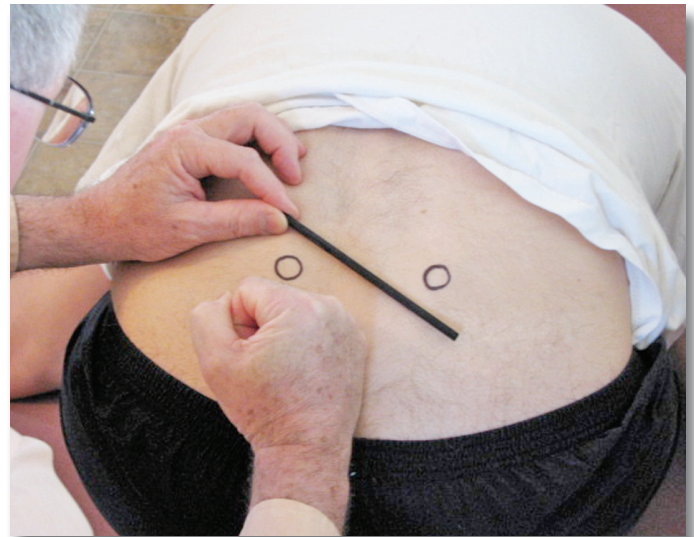


Figure 18: This photo shows **treatment for prominent and stuck left lower sacral quadrant, in yoga child pose**. The circles overlies the left and right PSIS. The heel of the hand or ulnar border of a fist is applied to the prominent and stuck left lower quadrant below the left oblique axis, using approximately 20 pounds of pressure for two minutes. Stacking hands is another option. Use whichever position feels most natural.

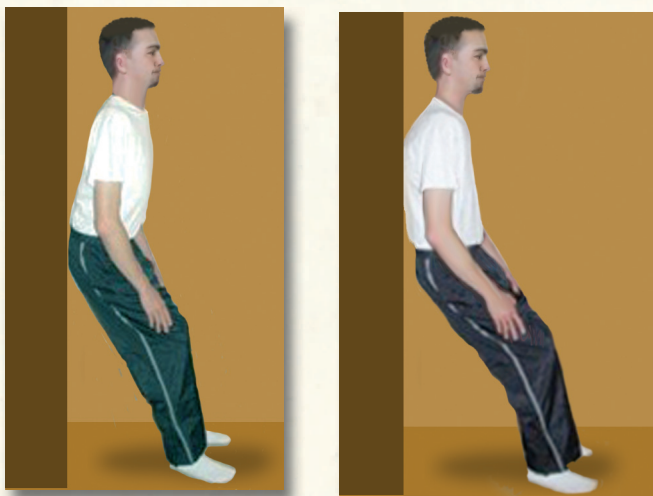

Figure 19: These images illustrate **self-treatment for all types of sacral torsion**. The client's feet are 18 inches in front of the wall to encourage maximal sacral contact. The most prominent quadrant contacts the wall initially, and a gentle mobilizing force is then isolated on that stuck quadrant. A pelvic tilt is performed 10 times with the sacrum against the wall, 10 times cycling from an anterior tilt to a posterior tilt. Repeat as needed or at least twice a week for prevention – perhaps once or twice daily for vulnerable occupations. Alternately, repeat trunk flexion and extension can be used with those clients who have difficulty performing a pelvic tilt.

^h Disclaimer: Clinicians who need to review the indications for treatment, as well as both relative and absolute contraindications to treatment, are encouraged to do so. Nearly any text on the topic will address them. Practitioners are also reminded to treat within the boundaries of their practice act. This chapter is for licensed health care practitioners, and not the general public, who should always consult their health care provider for care. The focused SIJ evaluation is only done after screening the lumbar spine and the hip, taking a thorough history, and conducting a physical exam and medical screen to rule out any non-musculoskeletal pathology. The team approach and inter-disciplinary communication is a necessary part of prudent care.

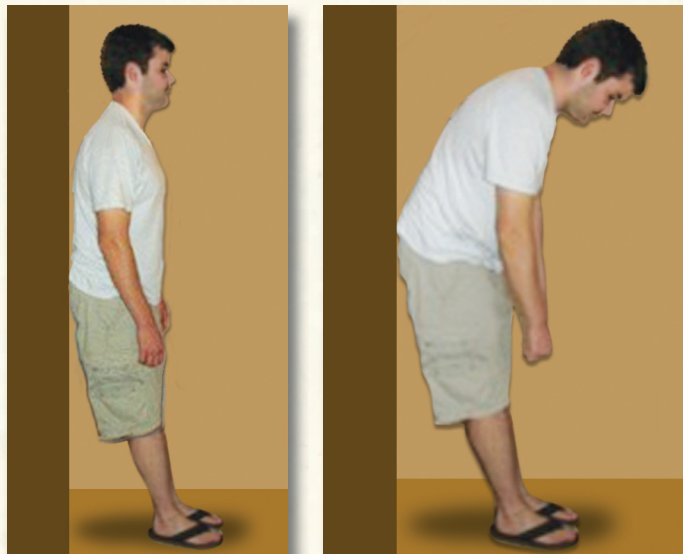

Figure 20: These images illustrate **self-treatment for all types of torsion using repeated trunk flexion**. The positioning is the same as Figure 19, except instead of using pelvic tilts to mobilize the sacrum, repeat trunk flexion of approximately 20 degrees accomplishes the same objective. The stuck and prominent quadrant makes initial contact with the wall, and a gentle mobilizing force is isolated at that quadrant. This is repeated 10 times and performed at least twice a week, or once or twice daily for vulnerable occupations.

Treatment for prominent and stuck left lower sacral quadrant, also known as left rotation about the left upper oblique axis, is outlined below.

Patient Position: Yoga child pose position, which is end-range flexion while sitting on heels with spine, hips, pelvis, and knees in full flexion

Therapist Contact: Heel of hand on left lower sacral quadrant

Force and Force Direction: Pure anterior glide using firm pressure of approximately 20 pounds, maintained for two minutes

Home Program: The torsion should resolve the first time. For prophylaxis, the client can stand with sacrum against a wall, in a one-quarter squat, with the heels 18 inches in front of the wall. This allows the sacrum to make nearly full contact against the wall.

The client is instructed to repeatedly extend, then flex the hips by approximately 15 degrees, to allow the pelvis to move into a posterior tilt, then an anterior tilt, maintaining sacral contact throughout these movements (Fig. 19). This should be repeated 10 times and performed at least twice a week – perhaps once or twice daily for vulnerable occupations. It is remarkably effective for the majority of clients. For those who cannot easily isolate a pelvic tilt, home treatment can be modified by performing 10 repetitions of trunk flexion to approximately 20 degrees (Fig. 20).

The self-treatment is incredibly simple, far simpler than the traditional approach detailed earlier in this chapter. The self-treatment is congruent with the philosophy of reducing patient dependency and fostering efficient self-management for simple injuries.

Treatment for prominent and stuck left upper quadrant, also known as left rotation on right oblique axis sacral torsion, is outlined below.

Patient Position: Yoga child pose position, which is end-range flexion while sitting on heels with spine, hips, pelvis, and knees in full flexion

Therapist Contact: Heel of hand on left upper sacral quadrant

Force and Force Direction: Pure anterior glide using firm pressure of approximately 20 pounds, maintained for two minutes

Home Program: The torsion should resolve the first time. For prophylaxis, the client can stand with sacrum against a wall, in a one-quarter squat, with the heels 18 inches in front of the wall. This allows the sacrum to make nearly full contact against the wall.

Repeatedly extend, then flex the hips by approximately 15 degrees to allow the pelvis to move into a posterior tilt, then an anterior tilt, maintaining sacral contact throughout (Fig. 19).

Repeat 10 times and perform at least twice a week – perhaps once or twice daily for vulnerable occupations. It is remarkable effective for the majority of clients. For those who cannot easily isolate a pelvic tilt, home treatment can be modified by performing 10 repetitions of trunk flexion to approximately 20 degrees (Fig. 20).

The self-treatment is incredibly simple, far simpler than the traditional approach detailed earlier in this chapter. The self-treatment is congruent with the philosophy of reducing patient dependency and fostering efficient self-management for simple injuries.

Treatment for prominent and stuck right upper sacral quadrant, also known as right rotation on left oblique axis sacral torsion, is outlined below.

Patient Position: Yoga child pose position, which is end-range flexion while sitting on heels with spine, hips, pelvis, and knees in full flexion

Therapist Contact: Heel of hand on right upper sacral quadrant

Force and Force Direction: Pure anterior glide using firm pressure of approximately 20 pounds, maintained for two minutes

Home Program: The torsion should resolve the first time. For prophylaxis, the client can stand with sacrum against a wall, in a one-quarter squat, with the heels 18 inches in front of the wall. This allows the sacrum to make nearly full contact against the wall.

Repeatedly extend, then flex the hips by approximately 15 degrees to allow the pelvis to move into a posterior tilt, then an anterior tilt, maintaining sacral contact throughout (Fig. 19). Repeat 10 times and perform at least twice a week – perhaps once or twice daily for vulnerable occupations. It is remarkable effective for the majority of clients. For those who cannot easily isolate a pelvic tilt, home treatment can be modified by performing 10 repetitions of trunk flexion to approximately 20 degrees (Fig. 20).

The self-treatment is incredibly simple, far simpler than the traditional approach detailed earlier in this chapter. The self-treatment is congruent with the philosophy of reducing patient dependency and fostering efficient self-management for simple injuries.

Treatment for prominent and stuck right lower sacral quadrant, also known as right rotation on right oblique axis sacral torsion, is outlined below.

Patient Position: Yoga child pose position, which is end-range flexion while sitting on heels with spine, hips, pelvis, and knees in full flexion

Therapist Contact: Heel of hand on right lower sacral quadrant

Force and Force Direction: Pure anterior glide using firm pressure of approximately 20 pounds, maintained for two minutes

Home Program: The torsion should resolve the first time. For prophylaxis, the client can stand with sacrum against a wall, in a one-quarter squat, with the heels 18 inches in front of the wall. This allows the sacrum to make nearly full contact against the wall.

Repeatedly extend, then flex the hips by approximately 15 degrees to allow the pelvis to move into a posterior tilt, then an anterior tilt, maintaining sacral contact throughout (Fig. 19). Repeat 10 times and perform at least twice a week – perhaps once or twice daily for vulnerable occupations. It is remarkable effective for the majority of clients. For those who cannot easily isolate a pelvic tilt, home treatment can be modified by performing 10 repetitions of trunk flexion to approximately 20 degrees (Fig. 20).

The self-treatment is incredibly simple, far simpler than the traditional approach detailed earlier in this chapter. The self-treatment is congruent with the philosophy of reducing patient dependency and fostering efficient self-management for simple injuries.

Discussion

Clinicians who are new to the paradigm of springing report a sense of comforting “objectivity” in discerning restricted spring/micro-motion, which was not otherwise on their radar. Noteworthy is the well-established fact that tension, compression, and inflammation influence the Type III and IV articular mechanoreceptors in inhibiting muscle function in agonists, as can occur with torsions and other types of SIJD. Thus, it is easy to encounter weak muscle groups that are reflexively inhibited, although not intrinsically weak. With this treatment paradigm, removing the inhibition is the first order of care, and a moderate return of strength is nearly always immediate.

With respect to physiological movement dysfunctions, an under-reported fact is that, typically, there will be one motion that is stuck, as identified by springing, and the opposite motion will be hypermobile. The joint is not singularly hypermobile, or singularly hypomobile. Like a coin that has two opposite sides, it is both. One or more ligaments will be taut, and the rest will be slack.

Many treatment paradigms are based on theories of pelvic joint hypermobility and instability. Although

true instability is valid in a small minority of the SIJD clients I have treated, the others typically respond with lasting benefit to simple intervention that positionally and reflexively stabilized the joint.

Restoring normative motion in the opposite direction – the direction that is actually stuck – also corrects the positionally and reflexively induced hypermobility. Positional hypermobility means there is reduced form- and force-closure of the joint,¹⁴⁶ with positionally induced ligamentous slack. Restoring normal position maximizes articular congruity, and ligamentous tone normalizes. At the same time, reflex inhibition of stabilizing muscle tone is removed.

At this point, the body reinforces correction through normative motion during daily functional activities and simple, brief self-treatment to reinforce the correction. Oftentimes, one to three visits accomplishes significant and lasting change, and then the client can progress rapidly through his or her rehabilitation, formally or informally, whichever is appropriate.



Conclusion

Hesch springing and treatment typically achieves significant initial efficiency, oftentimes resolving torsions and other SIJ movement dysfunction in one to three visits, as it does in other areas of the body as well. A client said this about my work: “Our bodies are fairly basic and logical for all their elegance in design. You know this and, therefore, your whole-body corrections are logical, direct, and efficient.”

The method came about through plumbing the depths of clinical theory and science and technique, along with protracted trial and error, believing there is a better way to approach the problem of SIJD. Some of my own vexatious, chronic injuries failed to respond to traditional and non-traditional care, so I had a need for empirical results.

My own efforts are undergirded by three decades of hands-on clinical practice in performing detailed evaluations to identify how the pelvic structure relates to proximal and distal pathomechanics, within a whole-body framework. I sometimes refer to this whole-body work as “connecting the dots,” or “realigning the body with its somatic template.”

There is an art to balancing the process of using one’s clinical knowledge to guide the evaluation and treatment process, while at the same time listening to the client’s body as its story is revealed. The philosophy of care embraces Gregory Grieve’s¹⁴⁷ commentary, paraphrased here: “*Dogma dulls the wits ... it is better to let the joints (and somatic structures) speak for themselves, rather than dictate to the joint how it is to behave based on various theories.*”

Noteworthy is the observation that pathomechanics and treatment of the pelvis and pelvic joints is not always a natural extension of normal mechanics. Thus, there is a knowledge gap in the education of biomechanically based health care practitioners. Many clinicians evaluate soft tissue tone on a daily basis, but neglect spring/micro-motion testing.

Springing is a parallel skill that and a very simple modification to what many clinicians are currently performing every day with great skill and commitment. Part of the Hesch Institute’s mission will be to raise awareness about springing through education, research, and clinical mentoring.

Springing is part of a basic skill set that should be accessible to manually oriented clinicians. Because there is an inherent lack of motor learning and kinesthetic sense in reading this chapter, practitioners can observe YouTube videos on the topic and attend continuing education seminars, or participate in distance learning.

Treatment of this region of the body is still evolving. This chapter focuses only on sacral torsions, though the overall theory, including spring/micro-motion testing, applies to all types of SIJD and pelvic pathomechanics. There is a fundamental dense connective tissue property named visco-elastic creep, which basically means that tissue changes slowly with applied force – and can change permanently, encouraging us to gently take up the slack in the elastic element, maintain a steady force for two to five minutes, and achieve lasting change.

This chapter sought to illustrate a problem faced by clinicians who are exposed to torsions, yet do not comprehend them enough to address them in clinical practice. Contemporary issues related to the general paradigm of SIJD are presented in this chapter, making a case that there is a dearth of research dealing specifically with torsions as they relate to objective imaging and clinical outcomes.

Clearer language, a few additional palpation tests, and Hesch Springing with AwarenessSM – an enhancement of traditional forward-thrust spring tests – were among the concepts presented. I believe that, if successful, this chapter will further the understanding of torsions, so that patient care is improved and research is facilitated. The novel torsion nomenclature is simple and direct, as is evaluation and treatment.

May those with protracted torsions be liberated, and may those with acute torsions avoid chronicity.

I wish to express a debt of gratitude to the osteopathic profession, and in particular to Philip Greenman, D.O., who greatly influenced my development as a hands-on clinician. I also thank my first mentor Richard DonTigny, P.T., and others, including William Brooks, D.O., Rina Luban, P.T., Cassie Benson, and Karen Nielsen.



References

1. Greenman, P.E. (1989). *Principles of Manual spondylitis on sacroiliac joint movement patterns*. Presented at 7th Interdisciplinary World Congress on Low Back and Pelvic Pain, Los Angeles, CA.
2. Schamberger, W. (2002). *The Malalignment Syndrome* (pp. 55-57). Edinburgh, Scotland: Churchill Livingstone.
3. Fryette, H. (1966). *Principles of Osteopathic Technic*. Carmel, CA: Academy of Applied Osteopathy.
4. Greenman, *Manual Medicine*, 227-229.
5. Mitchell, F. Sr. (1958). *Structural Pelvic Function* (pp. 72-90). Carmel, CA: Academy of Applied Osteopathy.
6. Mitchell, F. Jr., Moran, P., & Pruzzo, N. (1979). *An Evaluation and Treatment Manual of Osteopathic Muscle Energy Procedures*. Valley Park, MO: ICEOP.
7. Mitchell, F. Jr., & Mitchell, P. (1995). *The Muscle Energy Manual*. East Lansing, MI: MET Press.
8. Richard, R. (1986). Sacral lesions in torsion about an oblique axis. In R. Richard (Ed.), *Osteopathic Lesions of the Sacrum* (pp. 255-272). New York, NY: Thorsons Publishing.
9. Nyberg, R. (1989). Pelvic girdle. In O. Payton (Ed.), *Manual of Physical Therapy* (pp. 372-376). New York, NY: Churchill Livingstone.
10. Woerman, A.L. (1989). Evaluation and treatment of dysfunction in the lumbar-pelvic-hip complex. In R. Donatelli, & M. Wooden (Eds.), *Orthopaedic Physical Therapy* (pp. 496 & 500-504). New York, NY: Churchill Livingstone.
11. Schamberger, *Malalignment Syndrome*, 55.
12. Greenman, P. (1990). Clinical aspects of sacroiliac function in walking. *J Man Med*, 5(3), 127-129.
13. Maitland, G.D. (1986). *Vertebral Manipulation* (5th ed.), (pp. 314-317). London, United Kingdom: Butterworths.
14. DonTigny, R. (1979). Dysfunction of the sacroiliac joint and its treatment. *J Orthop Sports Phys Ther*, 1(1), 23-35.
15. DonTigny, R. (1985). Function and pathomechanics of the sacroiliac joint. *Phys Ther*, 65(1), 35-44.
16. DonTigny, R. (1990). Anterior dysfunction of the sacroiliac joint as a major factor in the etiology of idiopathic low back pain syndrome. *Phys Ther*, 70(4), 250-262.
17. Grieve, G. (1986). *Modern Manual Therapy of the Vertebral Column* (pp. 324-329). New York, NY: Churchill Livingstone.
18. Makofsky, H.W. (2003). *Spinal Manual Therapy* (p. 170). Thorofare, NJ: SLACK Incorporated.
19. Porterfield, J. (1985). The sacroiliac joint. In G. Davis, & J. Gould (Eds.), *Orthopedics and Sports Physical Therapy* (pp. 550-579). St Louis, MO: CV Mosby.
20. Porterfield, J., & DeRosa, C. (1990). The sacroiliac joint. In G. Davis, & J. Gould (Eds.), *Orthopedic and Sports Physical Therapy* (2nd ed.), (pp. 553-574). St Louis, MO: Mosby-Yearbook.
21. Porterfield, J., & DeRosa, C. (1991). *Mechanical Low Back Pain: Perspectives in Functional Anatomy*. Philadelphia, PA: W.B. Saunders.
22. Prather, H., & Hunt, D. (2010). Sacroiliac joint problems. In C.A. Guanche (Ed.), *Hip and Pelvis Injuries in Sports Medicine* (pp. 200-206). Philadelphia, PA: Lippincott Williams & Wilkins.
23. Bourdillon, J.F., & Day, E.A. (1987). *Spinal Manipulation* (4th ed.), (pp. 64-65). London, United Kingdom: William Heineman Medical Books.
24. Lewit, K. (1999). *Manipulation in Rehabilitation of the Locomotor System* (2nd ed.), (pp. 162-164). London, United Kingdom: Butterworth.
25. Levangie, P.K., & Norkin, C.C. (2005). The hip complex. In *Joint Structure & Function: A Comprehensive Analysis* (pp. 368-372). Philadelphia, PA: F.A. Davis.
26. Neumann, D. (2002). Axial skeleton: osteology and arthrology. In *Kinesiology of the Musculoskeletal System* (pp. 303-305). St Louis, MO: Mosby Inc.
27. Neumann, "Axial skeleton," 303.
28. Hesch, J., Aisenbrey, J., & Guarino, J. (1990, June). *The Pitfalls Associated With Traditional Evaluation of Sacroiliac Dysfunction and Their Proposed Solution*. Presented at Annual Conference of the American Physical Therapy Association, Anaheim, CA.

29. Hesch, J. (1992, November). *Manual therapy evaluation of the pelvic joints using palpatory and articular spring tests*. Presented at First Interdisciplinary World Congress on Low Back Pain and Its Relation to the Sacroiliac Joint, San Diego, CA.
30. Beal, M.C. (1982). The sacroiliac problem: review of anatomy, mechanics, and diagnosis. *J Am Osteopath Assoc*, 81(10), 73-85.
31. Jordan, T.R. (2006). Conceptual and treatment models in osteopathy II: sacroiliac mechanics revisited. *Am Acad Osteopath J*, 16(2), 11-17.
32. Greenman, *Manual Medicine*, 225 & 229.
33. Flynn, T.W., Cleland, J.A., & Whitman, J.M. (2008). *User's Guide to Musculoskeletal Examination: Fundamentals for the Evidence-Based Clinician* (pp. 196-217). Buckner, NY: Evidence in Motion.
34. Goode, A., Hegedus, E.J., Sizer, P., Brismee, J.M., Linberg, A., & Cook, C. (2008). Three-dimensional movements of the sacroiliac joints: a systematic review of the literature and assessment of clinical utility. *J Man Manip Ther*, 16(1), 25-38.
35. Huijbregts, P. (2004, May/June). Sacroiliac joint dysfunction: evidence-based diagnosis. *Orthopaedic Division Review*, 18-44.
36. Huijbregts, P. (2008). Evidence-based diagnosis and treatment of the painful sacroiliac joint. *J Man Manip Ther*, 16(3), 153-154.
37. Woerman, "Lumbar-pelvic-hip complex," 500.
38. Janiak, D.D. (2001). Review of sacral somatic dysfunction. *Am Acad Osteopath J*, 11(1), 18-23.
39. Educational Council on Osteopathic Principles. *Glossary of Osteopathic Terminology*. American Association of Colleges of Osteopathic Medicine. Retrieved August 25, 2011, from <http://www.aacom.org/resources/bookstore/Pages/glossary.aspx>
40. Cook, C. (2008). Philosophical differences in manual therapy. *J Man Manip Ther*, 16(1), 5-6.
41. Mintken, P., DeRosa, C., Little, T., & Smith, B. (2008). A model for standardizing manipulation terminology in physical therapy practice. *J Man Manip Ther*, 16(1), 50-56.
42. Hungerford, B. (2003). Evidence of altered lumbopelvic muscle recruitment in the presence of sacroiliac joint pain. *Spine*, 28(14), 1593-1600.
43. Scholtes, S.A., Norton, B.J., Lang, C.E., & Van Dillen, L.R. (2010). The effect of within-session instruction on lumbopelvic motion during a lower limb movement in people with and people without low back pain. *Man Ther*, 15(5), 496-501.
44. Reiman, M.P., Cox, K.D., Jones, K.S., & Byrd, J.W. (2011). Lumbo-pelvic-hip complex pain in a competitive basketball player: a case study. *Sports Health*, 3(1), 70-72.
45. Hesch, J. (2001-2011). *The Hesch Method of Treating Sacroiliac Joint Dysfunction: Integrating the Pelvis, SI, Symphysis Pubis, Hip and Lumbar Spine*. Seminar presented at the Hesch Institute, Henderson, NV.
46. Woerman, "Lumbar-pelvic-hip complex," 500-501.
47. Greenman, *Manual Medicine*, 247-248.
48. Goode, "Sacroiliac joints," 35.
49. Huijbregts, "Sacroiliac joint dysfunction," 18.
50. Cook, C., Massa, L., Harm-Ernandes, I., Segneri, R., Adcock, J., Kennedy, C., & Figuers, C. (2007). Interrater reliability and diagnostic accuracy of pelvic girdle pain classification. *J Manip Physiol Ther*, 30(4), 252-258.
51. Holmgren, U., & Waling, K. (2008). Inter-examiner reliability of four static palpation tests used for assessing pelvic dysfunction. *Man Ther*, 13(1):50-56.
52. Riddle, D.L., & Freburger, J.K. (2002). Evaluation of the presence of sacroiliac joint region dysfunction using a combination of tests: a multicenter intertester reliability study. *Phys Ther*, 82(8), 772-781.
53. Laslett, M. (2008). Evidence-based diagnosis and treatment of the painful sacroiliac joint. *J Man Manip Ther*, 16(3):142-152.
54. Robinson, H.S., Brox, J.I., Robinson, R., Bjelland, E., Solem, S., & Telje, T. (2007). The reliability of selected motion- and pain provocation tests for the sacroiliac joint. *Man Ther*, 12(1), 72-79.

55. Ivanov, A.A., Kiapour, A., Ebraheim, N.A., & Goel, V. (2009). Lumbar fusion leads to increases in angular motion and stress across sacroiliac joint: a finite element study. *Spine*, *34*(5), 162-169.
56. Lavignolle, B., Vital, J.M., Senegas, J., Destandau, J., Toson, B., Bouyx, P., ... Calabet, A. (1983). An approach to the functional anatomy of the sacroiliac joints in vivo. *Anat Clin*, *5*(3), 169-176.
57. Lumsden, R., & Morris, J. (1968). An in vivo study of axial rotation and immobilization at the lumbosacral joint. *J Bone Joint Surg*, *50*(8), 1591-1602.
58. Miller, J., Schultz, A., & Andersson, G. (1987). Load-displacement behavior of sacroiliac joints. *J Orthop Res*, *5*(1), 92-101.
59. Miles, M., & Sullivan, W.E. (1961). Lateral bending at the lumbar and lumbosacral joints. *Anat Rec*, *139*(3), 387-398.
60. Panjabi, M., Yamamoto, I., Oxland, T., & Crisco, J. (1989). How does posture affect coupling in the lumbar spine? *Spine*, *14*(9), 1002-1011.
61. Percy, M.J. (1985). Stereo radiography of lumbar spine motion. *Acta Orthop Scand Suppl*, *212*, 1-45.
62. Wang, M. (1998). Mechanical behavior of the female sacroiliac joint and influence of the anterior and posterior sacroiliac ligaments under sagittal loads. *Clin Biomech*, *13*(4-5), 293-299.
63. Weitz, E.M. (1981). The lateral bending sign. *Spine*, *6*(4), 388-397.
64. Wood, K.B., Schendel, M.J., Ogilvie, J.W., Braun, J., Major, M.C., & Malcom, J.R. (1996). Effect of sacral and iliac instrumentation on strains in the pelvis. A biomechanical study. *Spine*, *21*(10), 1185-1191.
65. Yamamoto, I., Panjabi, M., Crisco, J., & Oxland, T. (1989). Three-dimensional movements of the whole lumbar spine and lumbosacral joint. *Spine*, *14*(11), 1256-1260.
66. Stevens, A. (1992). Side-bending and axial rotation of the sacrum inside the pelvic girdle. In A. Vleeming, V. Mooney, C. Snijders, & T. Dorman (Eds.), Proceedings from: *First Interdisciplinary World Congress on Low Back Pain and its Relation to the Sacroiliac Joint* (pp. 209-230). San Diego, CA.
67. Stevens, A., & Vyncke, G. (1986). Sacrum rotation in the horizontal plane on lateral bending. Proceedings from: *8th Congress of the International Federation for Manual Medicine* (pp. 24 & 28). Madrid, Spain.
68. Stevens, "Side-bending," 228.
69. Mitchell, *Structural Pelvic Function*, 74.
70. Egund, N., Olsson, T.H., Schmid, H., & Selvid, G. (1978). Movements in the sacroiliac joints demonstrated with roentgen stereophotogrammetry. *Acta Radiol Diagn*, *19*(5), 833-846.
71. Stureson, B., Selvik, G., & Udén, A. (1989). Movements of the sacroiliac joints: a roentgen stereophotogrammetric analysis. *Spine*, *14*(2), 162-165.
72. Stureson, B., Udén, A., & Vleeming, A. (2000). A radiostereometric analysis of movements of the sacroiliac joints during the standing hip flexion test. *Spine*, *25*(3), 364-368.
73. Hesch, "World Congress."
74. Whitman, J., Flynn, T., Magel, J., Rendeiro, D., Butler, B., Wainner, R., & Allison, S. (2001, November). Does manual therapy experience influence reliability for selected pelvic girdle tests and measures? Proceedings from: *4th Interdisciplinary World Congress on Low Back & Pelvic Pain*. Montreal, Canada.
75. Olson, L. (1998). Effects from the Hesch method pelvic mobilization on lumbar flexion, straight leg raise performance, and standing pelvic inclination angles in patients with low back pain. (Doctoral dissertation). Finch University of Health Sciences/The Chicago Medical School, Chicago, IL.
76. Olson, L., & Kraemer, T.J. (2003, June). *Establishing the reliability of the Hesch method spring and positional tests in patients with low back pain*. Presented at 14th International Congress of the World Confederation for Physical Therapy, Barcelona, Spain.
77. Smidt, G.L., McQuade, K., Wei, S.H., & Barakatt, E. (1995). Sacroiliac kinematics for reciprocal straddle positions. *Spine*, *20*(9), 1047-1054.
78. Bussey, M.D., Yanai, T., & Milburn, P. (2004). A non-invasive technique for assessing innominate bone motion. *Clin Biomech (Bristol, Avon)*, *19*(1), 85-90.

79. Bussey, M.D., Bell, M.L., & Milosavljevic, S. (2010, November). The effect of ankylosing spondylitis on sacroiliac joint movement patterns. Presented at 7th Interdisciplinary World Congress on Low Back and Pelvic Pain, Los Angeles, CA.
80. Bussey, M.D. (2010). Does the demand for asymmetrical functional lower body postures in lateral sports relate to structural asymmetry of the pelvis? *J Sci Med Sport*, 13(3), 360-364.
81. Tullberg, T., Blomberg, S., Branth, B., & Johnsson, R. (1998). Manipulation does not alter the position of the sacroiliac joint. A roentgen stereophotogrammetric analysis. *Spine*, 23(10), 1124-1129.
82. Dar, G., Khamis, S., Peleg, S., Masharawi, Y., Steinberg, N., Peled, N. ... Hershkovitz, I. (2008). Sacroiliac joint fusion and the implications for manual therapy diagnosis and treatment. *Man Ther*, 13(2), 155-158.
83. Weinert, D.J. (2007). Influence of axial rotation on chiropractic pelvic radiograph analysis. *J Manip Physiol Ther*, 30(1), 78-79.
84. Lucas, B., Asher, M., McIlff, T., Lark, R., & Burton, D. (2005). Estimation of transverse plane pelvic rotation using a posterior-anterior radiograph. *Spine*, 30(1), E20-27.
85. Robbins, S.E., & Morse, M.H. (1996). Is the acquisition of a separate view of the sacroiliac joints in the prone position justified in patients with back pain? *Clin Radiol*, 51(9), 637-638.
86. Badii, M., Shin, S., Torreggiani, W., Jankovic, B., Gustafson, P., Munk, P.L., & Esdaile, J.M. (2003). Pelvic bone asymmetry in 323 study participants receiving abdominal CT scans. *Spine*, 28(12), 1335-1339.
87. Fafila, C.P., Prassopoulos, P.K., Daskalogiannaki, M.E., & Gourtsoyiannis, N.C. (1998). Variation in the appearance of the normal sacroiliac joint on pelvic CT. *Clin Radiol*, 53(10), 742-746.
88. Marshall, P., & Murphy, B. (2006). The effect of sacroiliac joint manipulation on feed-forward activation times of the deep abdominal musculature. *J Manip Physiol Ther*, 29(3), 196-202.
89. Suter, E., McMorland, G., Herzog, W., & Bray, R. (1999). Decrease in quadriceps inhibition after sacroiliac joint manipulation in patients with anterior knee pain. *J Manip Physiol Ther*, 22(3), 149-153.
90. O'Sullivan, P.B., Beales, D.J., Beetham, J.A., Cripps, J., Graf, F., Lin, I.B. ... Avery, A. (2002). Altered motor control strategies in subjects with sacroiliac joint pain during the active straight-leg-raise test. *Spine*, 27(1), E1-8.
91. Painter E.E., Ogle, M.D., & Teyhen, D.S. (2007). Lumbopelvic dysfunction and stress urinary incontinence: a case report applying rehabilitative ultrasound imaging. *J Ortho Sports Phys Ther*, 37(8), 499-504.
92. Hesch, J. (2010, November). Case studies: downslip ilium with paradoxical upslip ilium appearance, pudendal neuropathy, parainguinal neuropathy; a new internal sensory diagnostic test. Presented at 7th Interdisciplinary World Congress on Low Back and Pelvic Pain, Los Angeles, CA.
93. Neville, C. (2008). An interdisciplinary approach to treatment of a patient with chronic pelvic pain following gall bladder surgery: a case report. *J Women Health Phys Ther*, 32(2), 24-34.
94. Cibulka, M.T. (1999). Low back pain and its relation to the hip and foot. *J Ortho Sports Phys Ther*, 29(10), 595-601.
95. Voorn, R. (1998). Case report: can sacroiliac joint dysfunction cause chronic achilles tendinitis? *J Ortho Sports Phys Ther*, 27(6), 436-443.
96. Indahl, A., Kaigle, A., Reikeras, O., & Holm, S. (1999). Sacroiliac joint involvement in activation of the porcine spinal and gluteal musculature. *J Spin Disord*, 2(4), 325-330.
97. Wyke, B.D. (1972). Articular neurology: a review. *Physiotherapy*, 58(3), 94-99.
98. Sakamoto, N., Yamashita, T., Takebayashi, T., Sekine, M., & Ishii, S. (2001). An electrophysiologic study of mechanoreceptors in the sacroiliac joint and adjacent tissues. *Spine*, 26(20), 468-471.
99. Szadek, K.M., Hoogland, P.V., Zuurmond, W.W., de Lange, J.J., & Perez, R.S. (2008). Nociceptive nerve fibers in the sacroiliac joint in humans. *Reg Anesth Pain Med*, 33(1), 36-43.
100. Murakami, E., Tanaka, Y., Aizawa, T., Ishizuka, M., & Kokubun, S. (2007). Effect of periarticular and intraarticular lidocaine injections for sacroiliac joint pain: prospective comparative study. *J Orthop Sci*, 12(3), 274-280.

101. Stoddard, A. (1980). *Manual of Osteopathic Technique*. London, United Kingdom: Hutchinson.
102. Bernard, T. (1992, November). Sacroiliac joint injection. Presented at the First Interdisciplinary World Congress on Low Back Pain and Its Relation to the Sacroiliac Joint, San Diego, CA.
102. Walker, J.M. (1992). The sacroiliac joint: a critical review. *Phys Ther*, 72(12), 913.
103. Davis, P., & Lentle, B. (1978). Evidence for sacroiliac disease as a common cause of low backache in women. *The Lancet*, 312(8088), 496-497.
104. Depledge, J., McNair, P.J., Keal-Smith, C., & Williams, M. (2005). Management of symphysis pubis dysfunction during pregnancy using exercise and pelvic support belts. *Phys Ther*, 85(12), 1290-1300.
105. Eichner, E., Waltner, C., Goodman, M., & Post, S. (1956). Relaxin, the third ovarian hormone: its experimental use in women. *Am J Obstet Gynecol*, 71(5), 1035-1048.
106. Epstein, J.A. (1959). Treatment of low back pain and sciatic syndromes during pregnancy: a symposium. *NY State J Med*, 59(9), 1757-1768.
107. Farbrot, E. (1952). The relationship of the effect and pain of pregnancy to the anatomy of the pelvis. *Acta Radiol*, 38(5), 403-419.
108. Fast, A., Shapiro, D., Ducommun, E., Friedmann, L.W., Bouklas, T., & Floman, Y. (1987). Low-back pain in pregnancy. *Spine*, 12(4), 368-371.
109. Golightly, R. (1982). Pelvic arthropathy in pregnancy and puerperium. *Physiotherapy*, 68(7), 216-220.
110. Grose, A. (1986, January). Pelvic ring instability during pregnancy. Unpublished material.
111. Hagen, R. (1974). Pelvic girdle relaxation from an orthopedic view. *Acta Orthop Scand*, 45(4), 550-563.
112. Joseph, J. (1988). The joints of the pelvis and their relation to posture in labor. *Midwives Chron*, 101(1202), 63-64.
113. Laban, M.M., & Meerschaert, J.R. (1975). Lumbosacral-anterior pelvic pain with pubic symphysis instability. *Arch Phys Med Rehab*, 56, 48.
114. Lynch, F.W. (1920). The pelvic articulations during pregnancy, labor and puerperium: an X-ray study. *Surg Gynecol Obstet*, 30, 575-580.
115. MacLennan, A.H. (1983). The role of relaxin in human reproduction. *Clin Reprod Fertil*, 2(2), 77-95.
116. MacLennan, A.H. (1991). The role of the hormone relaxin in human reproduction and pelvic girdle relaxation. *Scan J Rheumatol Suppl*, 88, 7-15.
117. Quagliarello, J., Steinetz, B.G., & Weiss, G. (1979). Relaxin secretion in early pregnancy. *Obstet Gynecol*, 53(1), 62-63.
118. Sands, R. (1958). Backache of pregnancy. *Obstet Gynecol*, 12(6), 670-676.
119. Sicuranza, B., Richards, J., & Tisdall, L. (1970). The short leg syndrome in obstetrics and gynecology. *Am J Obstet Gynecol*, 107(2), 217-219.
120. Svensson, H.O., Andersson, G.B., Hagstad, A., & Jansson, P. (1990). The relationship of low-back pain to pregnancy and gynecologic factors. *Spine*, 15(5), 371-375.
121. Walheim, G. (1979). Pelvic instability after fracture and parturition. *Acta Orthop Scand*, 50, 362.
122. Weiss, G., O'Byrne, E.M., & Steinetz, B.G. (1976). Relaxin: a product of the human corpus luteum of pregnancy. *Science*, 194(4268), 948-949.
123. Young, L. (1940). Relaxation of the pelvic joints in pregnancy. *Brit J Obstet Gyneac*, 47, 493-524.
124. Badii et al., "Pelvic bone asymmetry."
125. Eustance, S., Coughlan, R.J., & McCarthy, C. (1993). Ankylosing spondylitis. *A comparison of clinical and radiographic features in men and women*. *Ir Med J*, 86(4), 120-122.
126. Wurdinger, S., Humbsch, K., Reichenbach, J.R., Peiker, G., Seewald, H.J., & Kaiser, W.A. (2002). MRI of the pelvic ring joints postpartum: normal and pathological findings. *J Magn Reson Imaging*, 15(3):324-329.
127. Coventry, M., & Tapper, E. (1972). Pelvic instability: a consequence of removing iliac bone for grafting. *J Bone Joint Surg Am*, 54(1), 83-101.
128. Ha, K.Y., Lee, J.S., & Kim, K.W. (1976). Degeneration of sacroiliac joint after instrumented lumbar or lumbosacral fusion: a prospective cohort study over five-year follow-up. *Spine*, 33(11), 1192-1198.
129. Macnab, I. (1981). Backache (pp. 64-78 & 217-218). Baltimore, MD: Williams & Wilkins.

130. Maigne, J.Y., & Planchon, C.A. (2005). Sacroiliac joint pain after lumbar fusion. A study with anesthetic blocks. *Eur Spine J*, 14(7), 654-658.
132. McGregor, M., & Cassidy, J.D. (1983). Post-surgical sacroiliac joint syndrome. *J Manip Physiol Ther*, 6(1), 1-11.
133. Zimmermann, T., Patzak, H.J., Kelm, C., Flechsenhar, K., & Kunze, K. (1992). Treatment of ruptures of the symphysis and iliosacral joint in pediatric patients. *Eur J Pediatr Surg*, 2(6), 348-351.
134. Hesch, J. (1996). Evaluating sacroiliac joint play with spring tests. *Ob Gyn PT*, 20(3). 4-7.
135. Vleeming, A., Van Wingerden, J.P., Snijders, C., Stoeckart, R., & Stijnen, T. (1989). Load application to the sacrotuberous ligament: influences on sacroiliac joint mechanics. *Clin Biomech*, 4, 204-209.
136. Hesch J. (1997). Evaluation and treatment of the most common pattern of sacroiliac joint dysfunction. In A. Vleeming, V. Mooney, T. Dorman, C. Snijders, & R. Stoeckart (Eds.), *Movement, Stability & Low Back Pain: The Essential Role of the Pelvis* (pp. 535-552). London, United Kingdom: Churchill Livingstone.
137. Huijbregts, "Sacroiliac joint dysfunction," 22-23.
138. Hesch, J. (2001-2011). *The Hesch Method of treating sacroiliac joint dysfunction: integrating the pelvis, SI, symphysis pubis, hip and lumbar spine*. Henderson, NV: Hesch Institute.
139. Greenman, *Manual Medicine*, 238.
140. Greenman, *Manual Medicine*, 239-241.
141. Makofsky, *Spinal Manual Therapy*, 7-8 & 11-12.
142. Keating, J., Matyas, T.A., Bach, T.M. (1993). The effect on training on physical therapists' ability to apply specific forces of palpation. *Phys Ther*, 73(1), 45-53.
143. Greenman, *Manual Medicine*, 240-241.
144. Greenman, *Manual Medicine*, 246.
145. Nyberg, "Pelvic girdle," 364-382.
146. Vleeming, A., Snijders, C., Stoeckart, R., & Mens, J. (1997). The role of the sacroiliac joint in coupling between spine, pelvis, legs and arms. In A. Vleeming, V. Mooney, T. Dorman, C. Snijders, C. Egund, & R. Stoeckart (Eds.), *Movement, Stability & Low Back Pain: The Essential Role of the Pelvis* (pp. 55-71). London, United Kingdom: Churchill Livingstone.
147. Grieve, G. (1981). *Common Vertebral Joint Problems* (pp. vii-x). New York, NY: Churchill Livingstone.